

EFFECT OF TESTOSTERONE REPLACEMENT ON EPITHELIAL AND STROMAL TISSUE

¹Yudi Irawan, ¹Aaron Tigor Sihombing.

¹Department of Urology, Faculty of Medicine/Padjadjaran University, Hasan Sadikin Hospital, Bandung, Indonesia.

ABSTRACT

Objective: To evaluate the effect of testosterone replacement on epithelial and stromal changes of prostatic lobes in castrated wistar rats. **Material & Method:** The subjects were 30 wistars equally assigned to castrated + testosterone replacement group (n = 10), castrated group (n = 10), and control group (n = 10). After 60 days, prostatectomy was performed in all rats and prostatic specimens were analyzed by haematoxylin eosin (HE) staining under microscope. Semi-quantitative analysis was performed by evaluating growth of epithelial structure and loss of fibromuscular stroma. Results were analyzed using ANOVA test method for normally distributed data. The statistical analysis was performed using SPSS. **Results:** There was significant reversibility in castration + testosterone replacement groups in all prostatic lobes compared with castration groups (p = 0,010). There were 5 rats showing normal structure of prostate gland compared to control groups in all prostatic lobes (50%), and 5 showed hyperplasia in all prostatic lobes (50%). **Conclusion:** Testosterone deprivation can cause prostatic atrophy. Dominant atrophy was found in ventral and lateral lobes. Testosterone replacement can prevent atrophy in all prostatic lobes regardless of specific prostatic lobes.

Keywords: Testosterone deprivation, testosterone replacement, prostatic lobes.

ABSTRAK

Tujuan penelitian: Mengevaluasi pengaruh terapi sulih testosteron pada epitel dan stroma masing-masing lobus pada prostat tikus wistar. **Bahan & cara:** Sampel sebanyak 30 wistar diberikan kastrasi + kelompok terapi testosteron (n = 10), kelompok kastrasi (n = 10), dan kelompok kontrol (n = 10). Setelah 60 hari, prostatektomi dilakukan pada semua kelompok dan spesimen lebih lanjut dari prostat yang dianalisa menggunakan pewarnaan haematoxylin eosin (HE) dibawah mikroskop yang dilakukan untuk analisa semi-kuantitatif, dengan mengevaluasi antara pertumbuhan struktur epitelial dan hilangnya stroma fibromuskular. Hasil penelitian dianalisa menggunakan metode tes ANOVA dengan data distribusi normal. Analisa statistik menggunakan SPSS. **Hasil penelitian:** Terdapat keterbalikan yang signifikan pada kastrasi + kelompok penggantian testosteron pada semua prostatic lobes dibandingkan dengan kelompok kastrasi (p = 0,010), selama penelitian terdapat 5 tikus kembali ke prostate gland struktur normal sama seperti kelompok kontrol pada semua prostatic lobes (50%), dan 5 lainnya muncul hyperplasia pada semua prostatic lobes (50%). **Simpulan:** Kekurangan testosteron dapat menyebabkan atrofi prostatik. Atrofi dominan ditemukan di ventral and lateral lobe. Penggantian testosteron dapat mencegah atrofi pada semua prostatic lobes tanpa perbedaan di specific lobe.

Kata kunci: Kekurangan testosteron, penggantian testosteron, prostatic lobes.

Correspondence: Yudi Irawan, c/o: Department of Urology, Faculty of Medicine/Padjadjaran University, Hasan Sadikin Hospital, Jl. Pasteur No. 38, Bandung, Indonesia. Phone. +62-22-2039141. Mobile phone: 0817206147

INTRODUCTION

The prostate is one of male sexual organs that is largely influenced by testosterone.¹⁻³ Most of the degenerative processes and malignancies in the human prostate is found on aging male. This has

been thought to be closely related to intraprostatic cellular interactions with sexual hormones as depicted in figure 1.

In normal conditions, the growth and development of the mammalian prostate is regulated by complex interaction of multiple factors namely

androgen hormones, growth factors, and stromal-epithelial interactions.^{1,2,4,5}

To date, most of existing studies is focused to the pathologic conditions of the human prostate, either malignancies or hyperplasia.^{3,6,8} This leads to the accumulation of knowledge in both of these conditions, yet complete comprehension of the physiologic growth and development of the prostate is still lacking.^{2-7,10,11}

Rodent prostate is an extensively studied organ in relation to various condition in those in humans due to its shared anatomical features (Fig. 2).^{3,6}

Correlation between growth, development, functions and pathological processes of prostate with testosterone is widely studies.¹⁻⁸ One of the most interesting aspects of which is the androgens, where the decrease of androgen concentration in blood will

cause significant involution process of the prostate.⁴⁻⁶ In contrast, androgen level increase will trigger prostatic growth, a process that is related to the life cycle and regeneration of prostatic stromal-epithelial cells.⁸⁻¹⁰

Prostatic cell growth and development in relation with testosterone have provided clinical implementations in the therapeutic armamentarium of benign prostatic hyperplasia and prostate cancer.^{3-6,8-11} Nevertheless, it is also known that each specific parts of the prostate does not exhibit uniform response to change of androgen levels. This has been thought due to the androgen receptor type and its distribution in various regions of the prostate and thus contribute in refractory effects and variable responses toward androgen deprivation therapy in both of the pathologic conditions.⁹⁻¹³

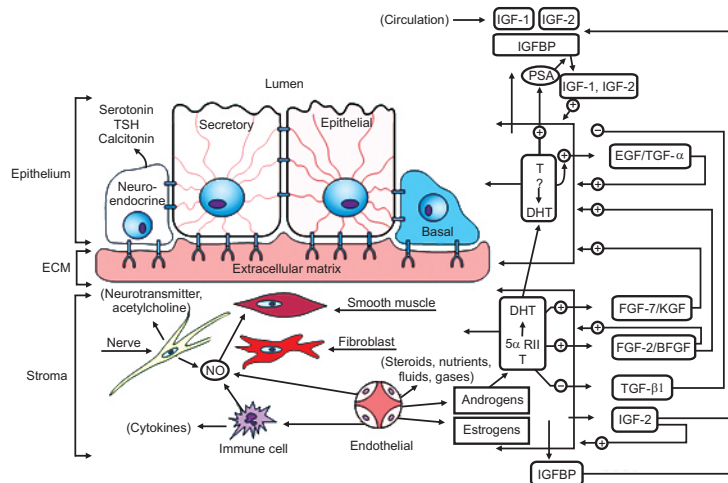


Figure 1. Prostatic stromal-epithelial interaction and its known mediators¹

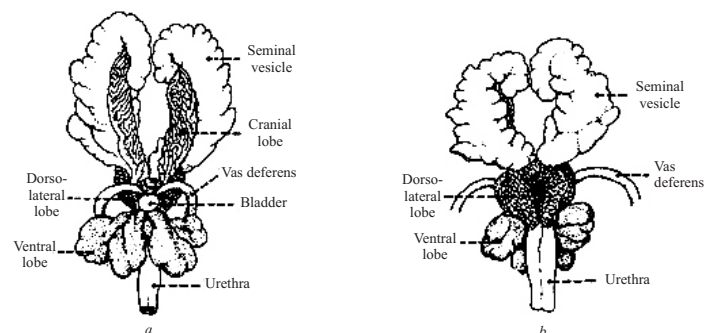


Figure 2. Schematic illustration of rat prostate (a. ventral. b. dorsal)

OBJECTIVE

To evaluate the effect of testosterone supplementation in stromal and epithelial component of orchidectomized Wistar rats.

MATERIAL & METHODS

The study was conducted from May–June 2011, at 30 adult Wistar rats, aged 6 weeks, weighed 200–300 gr, equally assigned to control group (n = 10) and treatment (castrated; n = 10 and castrated with supplemental testosterone administration; n = 10) group. Sample size was assigned using formula for 2 independent groups.

Each group were placed in the same cage, and subjected to seven days acclimatization period before undergoing bilateral orchidectomy. Daily subcutaneous testosterone replacement was administered using 100mg testosterone undecanoate (Nebido®).

After 60 days, the rats were humanely terminated and prostatectomy was performed in all groups. Subsequent specimens of the prostatic lobes was stained with haematoxylin eosin (HE) and taken to semi-quantitative pathology analysis using under Olympus CX 20 microscope by one experienced pathologist. Results were then grouped

into parametric data and analyzed using independent t-test with p value < 0,05 considered significant.

RESULTS

During study period, there is no significant differences in the mean body weight among study groups (Table 1), reflecting the homogeneity of the study population.

In terms of atrophy as summarized in table 2, a significant mean portion of prostatic tissue atrophy was exhibited in treatment group (25% in ventral lobe, 18% in lateral lobe, 13% in dorsal lobe, and 19% in all lobes; p = 0,01), whereas none in both control and treatment with testosterone supplementation group.

All the castrated wistars showed an obvious decrease of the epithelial component of the prostate tissue, with the atrophied prostatic lobe shown to be filled by extensive fibromuscular connective tissue while the stromal component increased particularly in the ventral and lateral lobes (table 2).

Five out of 10 castrated wistars that received testosterone replacement (50%), showed a similar stroma epithelial ratio in the prostate tissue on all lobes of the control groups. The other five wistars in this group (50%) showed epithelial hyperplasia prostatic lobes showed no evidence of fibromuscular stroma (table 3).

Table 1. Average weight of study sample.

Group	Body weight (gr)	SD	p
Control	260,6	4,278	0,047
Orchidectomy	265,7	11,106	
Orchidectomy + testosterone	2545	10,896	

Table 2. Post-orchidectomy average prostatic lobe atrophy.

Group	Mean atrophy of prostatic tissue (%)				p
	Ventral	Lateral	Dorsal	Total	
Control	-	-	-	-	0,010
Treatment	25	18	13	19	

Table 3. Post-orchidectomized prostatic lobe examination result after supplemental testosterone administration.

Study group	Prostatic lobe examination	p
Orchidectomy + supplemental testosterone	5 wistars exhibit normal histologic findings (50%) at all prostatic lobes 5 wistars exhibit hyperplasia at all prostatic lobes	0,010

Histological findings can be seen in figure 3, 4, and 5.

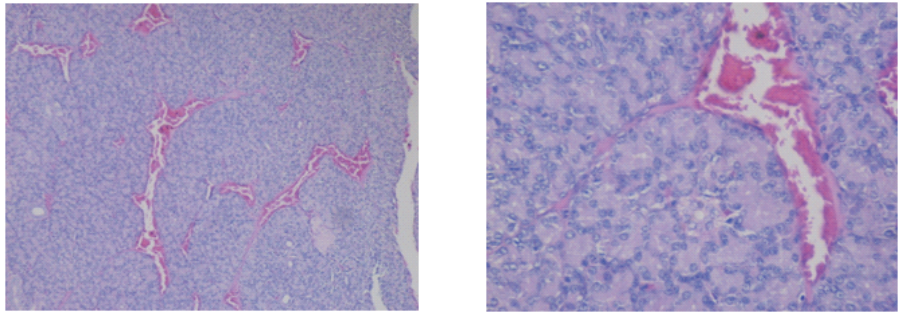
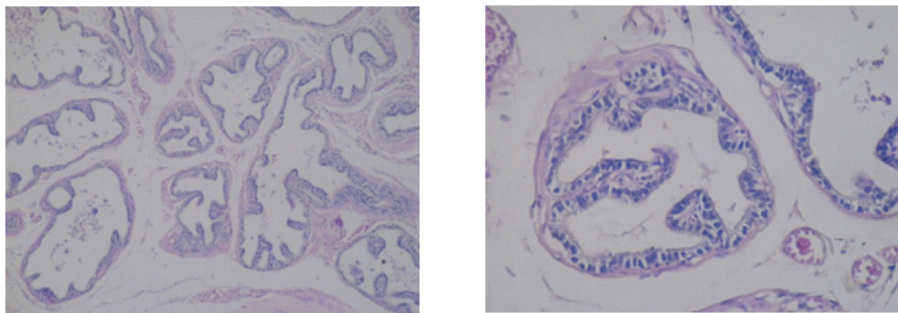
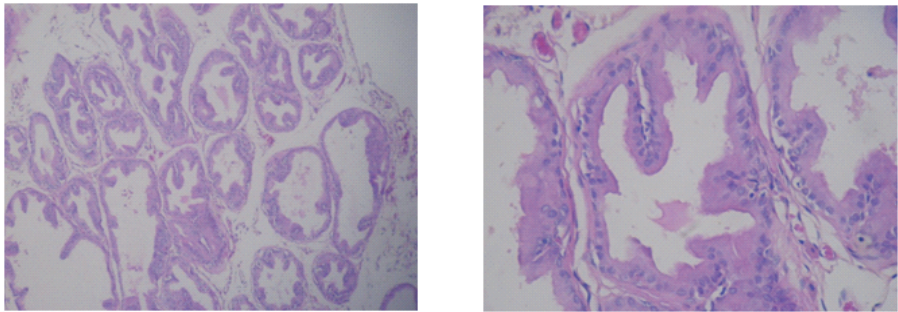


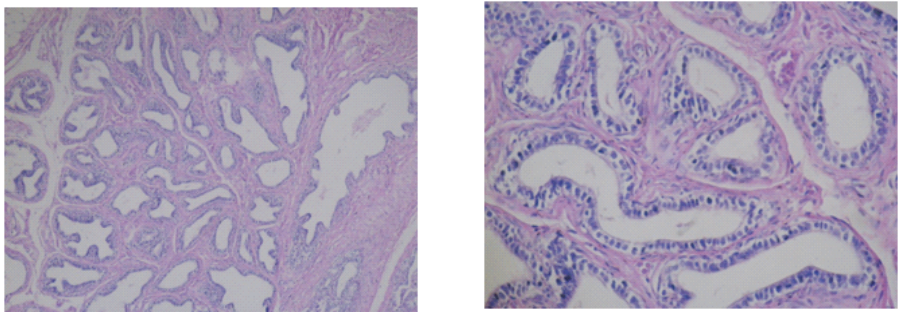
Figure 3.Prostatic lobe HE staining in control group.



a.Ventral lobe



b.Lateral lobe



c.Dorsal lobe

Figure 4. HE staining results for orchidectomized wistar group.

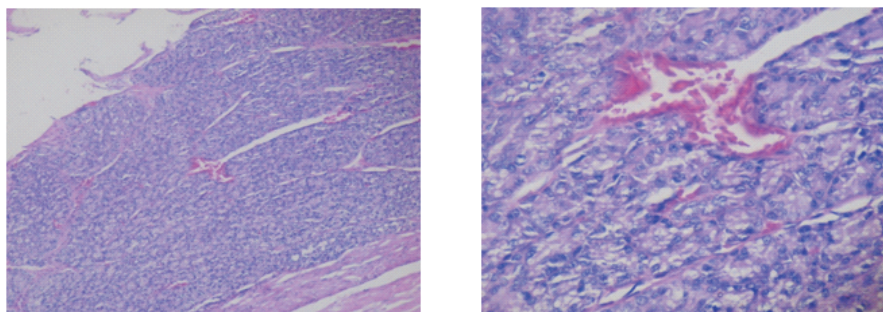


Figure 5. Prostatic lobe HE staining for the orchidectomized with testosterone supplement group.

DISCUSSION

Testosterone deprivation achieved by surgical castration is proven to cause prostatic epithelium degeneration. This was thought to be mediated by activation of apoptotic cascade.²⁻⁵ Several studies utilizing apoptotic biomarkers has shown that prostatic apoptosis can be detected starting from the first 24 hours post-castration and will peak in three days after. At a week after castration, the prostatic gross volume has already shown significant involution, but retaining its pre-castration amount of basal and secretory cells.⁵⁻⁷

Apoptosis of prostatic tissue ultimately encompasses all cell populations of the prostate. The first affected prostatic component in this regard is found to be glandular epithelium, followed by stromal smooth muscle cells and other supportive components.⁵

Other studies utilizing vascular endothelial growth factors (VEGFs) has stated that apoptosis is actually a secondary process caused mainly by declining blood supply of the prostate, which integrity is maintained throughout by paracrine interaction of prostatic components that are regulated in part by testosterone.⁹ The contrary occurs on testosterone supplementation that maintains blood supply to the prostate, and to certain extent, was proven to reverse.^{10,11-14} Nonetheless, there are conflicting reports on how this fundamental process affects the rat prostate as a whole, with some statements that the prostatic involution and subsequent reversal is observed to be focused in the ventral and dorsolateral lobes,^{3,4,12} while others found that due to the relatively homogenous cell population of rat prostate, the gross reversal of rat prostate is diffuse and not contained to specific lobes.^{5,9,13}

CONCLUSION

Testosterone deprivation causes prostatic atrophy with dominant atrophy found in ventral and lateral lobes. Furthermore testosterone replacement was found to prevent atrophy in all prostatic lobes without any difference on specific lobes.

REFERENCES

1. Veltri R, Rodriguez R. Molecular biology, endocrinology, and physiology of the prostate and seminal vesicles. In: Kavoussi LR, Novick AC, Partin AW, Peters CA, editors. *Campbell-Walsh Urology*: Saunders; 2007 (85).
2. Rudolfsson SH, Bergh A. Testosterone-stimulated growth of the rat prostate may be driven by tissue hypoxia and hypoxia-inducible factor-1a. *Journal of Endocrinology*. 2008; 196: 11–19.
3. Adesanya OA, Kayode AO, Dare NW, Lukeman AJS, Olusoji AO, Abayomi OO. Sex steroid induced changes on the morphology of prostate of sprague-dawley rats. *Scientific Research and Essay*. 2007; 2(8): 309-14.
4. Lissbrant IF, Häggström S, Damber JE, Bergh A. Testosterone stimulates angiogenesis and vascular regrowth in the ventral prostate in castrated adult rats. *Endocrinol*. 1998; 139: 451-6.
5. Antonioli E, Heloisah M, Colleta D, Carvalho HF. Smooth muscle cell behavior in the ventral prostate of castrated rats. *J Androl*. 2004; 25(1).
6. Banerjee S, Banerjee PP, Brown TR. Castration-induced apoptotic cell death in the brown Norway rat prostate decreases as a function of age. *Endocrinol*. 2000; 141: 821-32.
7. Banerjee PP, Banerjee S, Brown TR. Increased androgen receptor expression correlates with development of age-dependent, lobe-specific spontaneous hyperplasia of the brown Norway rat prostate. *Endocrinol*. 142(9): 4066–75.

8. Garcia Florezl M, Oliveira CA, Carvalho HF. Early effects of estrogen on the rat ventral prostate. *Brazilian J Med Biol Res.* 2005; 38: 487-97.
9. Kumar VL, Majumder PK, Kumar V. In vivo modulation of androgen receptor by androgens. *Asian J Androl.* 2002; 4: 229-31.
10. Omezzine A, Mauduit C, Tabone E, Nabli N, Bouslama A, Benahmed M. Caspase-3 and -6 expression and activation are targeted by hormone action in the rat ventral prostate during the apoptotic cell death process. *Biol Rep.* 2003; 69: 752-60.
11. Justulin LA, Rodrigo P, Ureshino, Zaroni M, Felisbino SL. Differential proliferative response of the ventral prostate and seminal vesicle to testosterone replacement. *Cell Biol Int.* 2006; 30: 354-64.
12. Nieschlag E, Behre HM. Testosterone action, deficiency, substitution. Cambridge University Press; 2004.
13. Santos FCA, Leite RP, Custódio AMG, Carvalho KP, Monteiro-Leal LH. Testosterone stimulates growth and secretory activity of the female prostate in the adult gerbil (*Meriones unguiculatus*). *Biol Rep.* 2006; 75: 370-9.
14. Wright AS, Douglas RC, Thomas LN, Lazier CB, Rittmaster RS. Androgen-induced regrowth in the castrated rat ventral prostate: Role of 5 α -reductase. *Endocrinol.* 1999; 140: 4509-15.