

LAPAROSCOPIC PYELOLITHOTOMY AND Y-V PYELOPLASTY IN PATIENT WITH LARGE PYELUM CALCULI AND UPJO

¹Firman Nugroho, ¹Sawkar Vijay Pramod.

¹Department of Urology, Faculty of Medicine/ University of Padjadjaran, Hasan Sadikin Hospital Bandung.

ABSTRACT

Objective: We report our experience in laparoscopic pyelolithotomy with Y-V pyeloplasty. **Case(s) Presentation:** A 35 years old man with a chief complained of right flank pain since 1 year ago and worsened since 3 months before admission. KUB-IVU showed right hydronephrosis, pyelum calculi, and UPJO. We performed Laparoscopic Pyelolithotomy and Y-V Pyeloplasty. Operative time was 180 minutes and blood loss was about 50 cc. Drain was removed at post-operative day 4. Operating wound was good, maximum VAS score was 3. Patient was discharged at post-operative day 4. **Discussion:** Y-V plasty technique significantly reduces surgery time and has lower risk of devascularization of the UPJ. The success of the Y-V plasty depends on proper placement of the incision ensuring a broad-based flap of pelvis. Following incision the apex of the flap is advanced and secured with an interrupted suture ensuring no tension. The remaining gaps are then closed in an interrupted fashion. **Conclusion:** Laparoscopic Pyelolithotomy for large stone with Y-V Pyeloplasty was safe and effective alternative treatment of large pyelum calculi and UPJO.

Keywords: Laparoscopic Pyelolithotomy, large stone, Y-V Pyeloplasty.

ABSTRAK

Tujuan: Kami melaporkan pengalaman kami dalam laparoskopi pyelolithotomy dengan Y-V pyeloplasty. **Presentasi Kasus:** Seorang laki-laki berusia 35 tahun dengan keluhan utama nyeri pinggang kanan sejak 1 tahun yang lalu dan memburuk sejak 3 bulan sebelum masuk rumah sakit. KUB-IVU menunjukkan hidronefrosis kanan, batu pyelum, dan UPJO. Kami melakukan Laparoskopi Pyelolithotomy dan Y-V Pyeloplasty. Waktu operasi adalah 180 menit dan kehilangan darah sekitar 50 cc. Drain dikeluarkan pada hari ke-4 pasca operasi. Luka operasi baik, skor VAS maksimum adalah 3. Pasien dipulangkan pada hari ke-4 pasca operasi. **Diskusi:** Teknik plasti Y-V secara signifikan mengurangi waktu operasi dan memiliki risiko devaskularisasi UPJ yang lebih rendah. Keberhasilan plasti Y-V tergantung pada penempatan sayatan yang tepat untuk memastikan lipatan panggul yang lebar. Setelah insisi, puncak flap dimajukan dan diamankan dengan jahitan terputus untuk memastikan tidak ada ketegangan. Kesenjangan yang tersisa kemudian ditutup secara terputus-putus. **Simpulan:** Pyelolithotomy laparoskopi untuk batu besar dengan Y-V Pyeloplasty adalah pengobatan alternatif yang aman dan efektif untuk batu pyelum besar dan UPJO.

Kata Kunci: Laparoskopi pyelolithotomy, batu besar, Y-V pyeloplasty.

Correspondence: Firman Nugroho; c/o: Department of Urology, Faculty of Medicine/University of Padjadjaran, Hasan Sadikin General Hospital, Jl. Pasteur No.38, Sukajadi, Bandung, Jawa Barat 40161, Indonesia. Email: nugroho.firman@gmail.com.

INTRODUCTION

Kidney stone is a hard mass that forms from crystals in urine. The main etiology of kidney stone is supersaturation of urine and their composition varies but the most common types are largely made up of different forms of calcium. The initial presentation of kidney stone is often present with pain in the flank area, hematuria, and may be

accompanied by nausea and vomiting.¹ There are some surgical treatment modalities for kidney stone, the appropriate modality depends on the size, location, type of stone, and the presence of anatomical abnormalities.²

A ureteropelvic junction obstruction (UPJO) is an impediment to urine flow at the junction of the ureter and renal pelvis that leads to progressive dilation of the collecting system.

Possible causes for UPJO are stenosis due to scarring ureteral valves, ureteral hypoplasia, an abnormal or high insertion of the ureter into the renal pelvis, crossing lower-pole renal vessels or entrapment of the ureter by a vessel can prohibit urinary flow down the ureter, rotation of the kidney and renal hypermobility, and ureteral obstruction caused by stone. The treatment for UPJO is surgery to correct the blockage allows urine to flow normal. The procedures include laparoscopic pyeloplasty, open pyeloplasty, endopyelotomy, endopyeloplasty, and robotic-assisted laparoscopic pyeloplasty. Laparoscopic pyeloplasty is the treatment of choice in adults because of the optimal cosmetics, less post-operative morbidity, shorter hospitalization, less discomfort, and more rapid convalescence.^{3,4}

Several treatment modalities have been established for managing different types of renal stones, based on stone location and distribution, such as, ESWL, percutaneous nephrolithotomy (PNL) and ureterorenoscopy (URS).⁵ Sometimes, it needed more than one session to clearing stones with these techniques because of the complexity of stone distribution within the kidney. It will cause more complications and more expenditure. For instance, percutaneous nephrolithotomy (PNL) is associated with massive bleeding perioperatively and renal parenchymal injury.⁶ Therefore, laparoscopic pyelolithotomy (LP) is a alternative procedures to manage renal stones, especially in cases of concomitant UPJO.⁷

The “gold standard” therapy for UPJO has been the open pyeloplasty with success rates consistently greater than 90% for all types.⁸ Fenger plasty or Foley Y-V procedures, which involve less suturing and are technically easier, have been found equally efficacious with dismembered pyeloplasty.⁹

In this study, we report a case of large pyelum calculi with UPJO, which treated by laparoscopic pyelolithotomy and Y-V pyeloplasty.

CASE(S) PRESENTATION

A 35 years old man with a chief complained of right flank pain since 1 year ago and worsened since 3 months before admission. KUB-IVU showed right hydronephrosis, pyelum calculi, and ureteropelvic junction obstruction (UPJO). The diagnosis of hydronephrosis in the course of UPJO was based on a complete medical history,

ultrasonography, and diuretic urography (IVU). There is a clinically significant obstruction UPJ and dilatation of the pelvicaliceal system with delayed excretion on the affected side. We then performed laparoscopic pyelolithotomy and Y-V pyeloplasty.

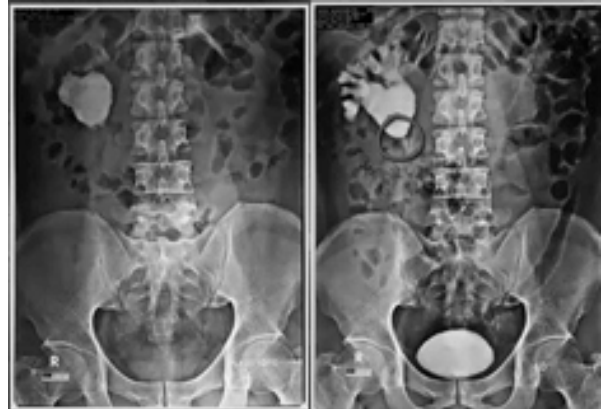

Figure 1. KUB-IVU shows right pyelum calculi and UPJO.

No bowel preparation was performed. After induction of general anesthesia. The patient is on the flank position with the ipsilateral side rotated up approximately 20- degrees. We placed an axillary role and padded pressure points, on the other hand, the table is flexed slightly at the hips. The patient is secured to the table using wide cloth tape at the lower extremities, hips and shoulders. This allows for the patient to be rotated from a relatively horizontal position to the flank position by simply rotating the table. The abdomen and flank is prepped in the usual sterile fashion.

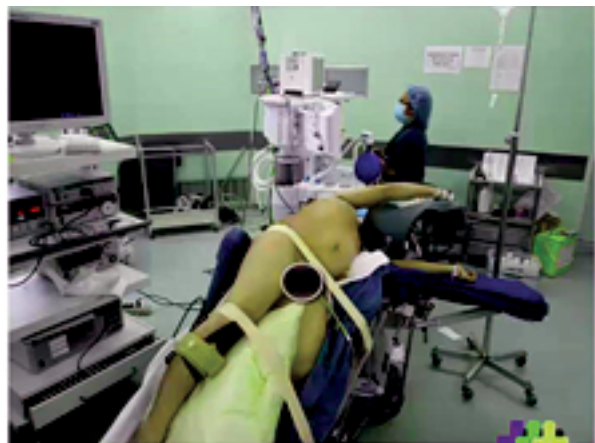

Figure 2. Patient position.



Figure 3. Port position.

We used transperitoneal approach to ease of exposure of the UPJ. First 10-mm trocar was introduced below the umbilicus using a Hasson technique. After achieving the pneumoperitoneum, We use 2 10-mm port and 2 5-mm port.

The posterior peritoneum was incised lateral to the edge of the colon and we exposed the bloodless

plane between Gerota's fascia and the mesentery. The colon was gently mobilized medially and Gerota's fascia was incised and entered. The renal pelvis and proximal ureter were identified. We can identified hydronephrotic kidney located posterior and lateral to the colon. The posterior peritoneum overlying the kidney is divided from the upper pole to a distance approximately 4 cm below the lower pole. The renocolic ligaments are divided allowing the colon to passively move medially and provide clear exposure to the UPJ.

Once the ureter has been identified by following the psoas muscle to a point just medial to the lower pole of the kidney, it is freed in a cephalad direction toward the UPJ. We performed laparoscopic pyelolithotomy and Y-V pyeloplasty.

Two incisions were made on the anterior aspect of the renal pelvis. The apex of the V was located close to the UPJ and the wings of the V were formed by two incisions: one toward the upper calix and the other in the direction of the lower calix. Then the vertical incision was carried down the anterior proximal ureter as low as 1 cm below the area of stenosis.

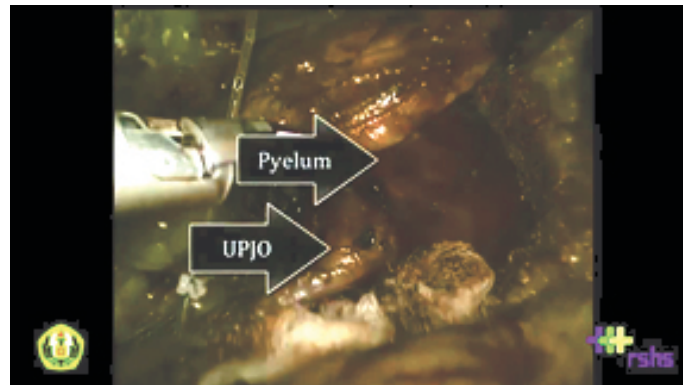


Figure 4. Intraoperative finding of the right UPJO.

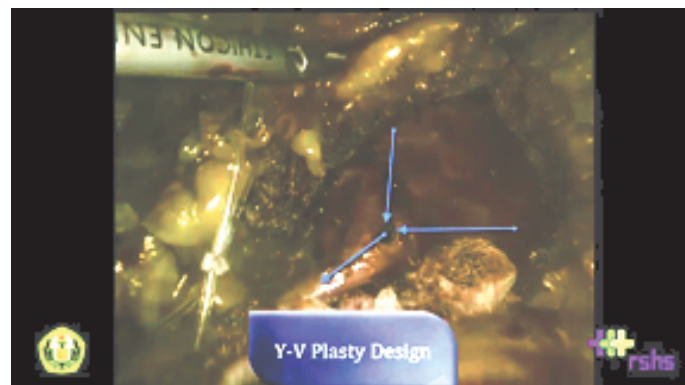


Figure 5. Y-V plasty design.

The apex of the pelvic flap was approximated to the apex of the ureterotomy incision by the first suture. The anastomoses of the medial and lateral walls were then performed with interrupted sutures over a Double-J stent. The suturing material preferred by the authors was 4-0 monofilament suture with a curved needle. In the procedure, the ureter is not completely transected from the renal pelvis, fewer sutures are needed to perform anastomosis

At the end of the procedure, a 5-mm closed suction drain was positioned close to the anastomosis and a 16F urethral catheter was left indwelling. The urethral catheter was removed the next day. Overall, operative time was 180 minutes and blood loss was about 50 cc. Drain was removed at post-operative day 4. Operating wound was good, maximum VAS score was 3. Patient was discharged at post-operative day 4. After 3 month postoperative, we performed KUB-IVU with no residual contrast were found in the right kidney.

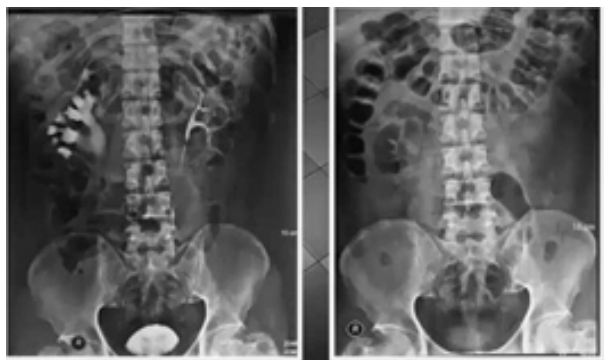

Figure 6. Postoperative KUB-IVU shows no residual contrast on the right kidney.

DISCUSSION

In this study, we performed a laparoscopic pyelolithotomy and Y-V pyeloplasty to manage large pyelum calculi with UPJ obstruction to achieve complete stone clearance in one session. Laparoscopic pyelolithotomy is a challenging procedure but safe operation in the hands of an experienced laparoscopist. Laparoscopic pyelolithotomy can be useful treatment for renal calculi not amenable to more common surgical procedure. It has advantages such as optimal cosmetics, less post-operative morbidity, shorter hospitalization, less discomfort, and more rapid convalescence. In particular, the technique can be

beneficial in patients who have renal anomalies and have a large single renal-pelvic calculus.¹⁰

We also performed Y-V pyeloplasty to treat UPJ obstruction. Studies thus far indicate the approach is as efficacious as its open surgical counterpart when applied for the treatment of UPJ obstructions. It also may have some advantages over other surgery technique, such as dismembered pyeloplasty. The procedure is less traumatic to the ureter's vasculature since the incision is mostly longitudinal as is the course of the ureteral vessels.¹¹ Branches of the renal artery is the major blood supply to the ureter, so it may be advisable to preserve these vessels, although there is no direct evidence that damaging these vessels could lead to suboptimal outcomes of pyeloplasty or increase the incidence of reobstruction.

On the other hand, Y-V pyeloplasty will not be damaged nerve impulse conduction along the ureter, since the ureter is not transected, thus preserving the physiological peristalsis.¹²⁻¹³ Furthermore, Y-V pyeloplasty is technically quite a simple procedure compared with other dismembered techniques. In dismembered pyeloplasty, correct realignment of the ureter is more complicated and difficult than in Y-V pyeloplasty, where the limbs of the incision stay aligned constantly.

In general, Y-V plasty technique significantly reduces surgery time and has lower risk of devascularization of the UPJ. The success of the Y-V plasty depends on proper placement of the incision ensuring a broad-based flap of pelvis. Following incision the apex of the flap is advanced and secured with an interrupted suture ensuring no tension. The remaining gaps are then closed in an interrupted fashion.

CONCLUSION

Laparoscopic Pyelolithotomy for large stone with Y-V Pyeloplasty was safe and effective alternative treatment of large pyelum calculi and UPJO.

REFERENCES

1. Worcester EM, Coe FL. Nephrolithiasis. *Prim Care.* 2008; 35(2):369-v11.
2. Auge BK, Preminger GM. Surgical management of urolithiasis. *Endocrinol Metab Clin N Am.* 2002; 31: 1065-1082.

3. Symons SJ, Bhirud PS, Jain V, Shetty AS, Desai MR. Laparoscopic pyeloplasty: our new gold standard. *J Endourol.* 2009 Mar. 23(3): 463-7.
4. Khan F, Ahmed K, Lee N, Challacombe B, Khan MS, et al. Management of ureteropelvic junction obstruction in adults. *Nature Reviews Urology.* 2014; 11: 629-638.
5. Kiivikai K. The role of laparoscopic surgery for renal calculi management. *Ther Adv Urol.* 2011; 3: 13-8.
6. Shahrou K, Tomaszewski J, Ortiz T, Scott E, Sternberg KM, et al. Predictors of immediate postoperative outcomes of single tract percutaneous nephrolithotomy. *Urology.* 2012; 80: 19-26.
7. Salvado JA, Guzman S, Trucco CA, Parra CA. Laparoscopic pyelolithotomy: optimizing surgical technique. *J Endourol.* 2009; 23: 575-8.
8. Rassweiler JJ, Subotic S, Feist-Schwenk M, et al. Minimally invasive treatment of ureteropelvic junction: Long term experience with algorithm for laser endopyelolithotomy and laparoscopic retroperitoneal pyeloplasty. *J Urol.* 2007; 177: 1000-5.
9. Szydelko T, Kasprzak J, Apoznanski W, Zdrojowy R. Laparoscopic anterior Y-V pyeloplasty: A valuable treatment option in patients with small or intrarenal pelvis. *J Laparoendosc Adv Surg Tech* 2010. 20(7): 627-630.
10. Kramer BA, Hammond L, Schwartz BF. Laparoscopic pyelolithotomy: Indications and technique. *J of Endourol.* 2007; 21(8): 860-1.
11. Jarrett TW, Chan DY, Charambura TC, et al. Laparoscopic pyeloplasty : The first 100 cases. *J Urol.* 2002; 167: 1253-6.
12. Salvado JA, Guzman S, Trucco CA, Parra CA. Laparoscopic pyelolithotomy: optimizing surgical technique. *J Endourol.* 2009; 23: 575-8.
13. Goel A, Hemal AK. Evaluation of role of retroperitoneoscopic pyelolithotomy and its comparison with percutaneous nephrolithotripsy. *Int Urol Nephrol.* 2003; 35: 73-6.