

EFFECT OF VITAMIN E (α TOCOPHEROL) ADMINISTRATION ON APOPTOSIS OF GERMINAL CELLS EPITHELIUM TESTIS IN SPRAGUE DAWLEY WHITE STRAIN RATS AFTER EXPOSED BY CISPLATIN

¹Achmad Nugroho, ¹Wahjoe Djatisoesanto, ¹Doddy M. Soebadi.

¹Department of Urology, Faculty of Medicine/Universitas Airlangga, Soetomo General Hospital, Surabaya.

ABSTRACT

Objective: To determine the differences of germinal epithelial testicular cell apoptosis in white Sprague Dawley strain rat that received combination of cisplatin and vitamin E compared to Sprague Dawley strain rat that received cisplatin only. **Material & Methods:** Twenty four Sprague Dawley rats were divided into 4 groups randomly. Group 1 Negative Control (NC) was given an injection of 1 cc 0.9% normal saline intraperitoneally as a placebo, group 2 Positive Control (PC) was given 5 mg/kgBW cisplatin intraperitoneally, group 3 (P1) was given cisplatin injection 5 mg/kgBW intraperitoneally + vitamin E (α tocopherol) 50 mg/kgBW by gavage and group 4 (P2) was given cisplatin injection 5 mg/kgBW intraperitoneally + vitamin E (α tocopherol) 200 mg/kgBW by gavage. Vitamin E (α tocopherol) was given 3 weeks before up to 4 weeks after cisplatin injection. Observation of the germinal epithelial cells apoptosis was carried out by calculating germinal epithelial cells apoptosis in the cross-section preparations of the seminiferous tubule which gave a positive reaction to the apoptag staining, using a 400x magnification light microscope. **Results:** Apoptosis on positive control (PC) group was different significantly compared to the negative control (NC) group ($p < 0.05$). There was a significant difference in the apoptosis of germinal epithelial testicular cells in the cisplatin + vitamin E 50 mg/kgBW compared to the PC group ($p < 0.05$). The cisplatin + vitamin E 200 mg/kgBW group; had a lower number of apoptosis compared to the cisplatin + vitamin E 50 mg/kgBW ($p < 0.05$). **Conclusion:** Vitamin E provides a protective effect on decreasing the amount of apoptosis due to cisplatin exposure. The protective effect of vitamin E is dose-dependent.

Keywords: Apoptosis, cisplatin, vitamin E.

ABSTRAK

Tujuan: Untuk mengetahui perbedaan jumlah apoptosis sel germinal epithelial testis pada tikus Sprague Dawley yang mendapatkan kombinasi cisplatin dan vitamin E dibandingkan dengan yang hanya mendapatkan cisplatin. **Bahan & Cara:** Sampel pada penelitian ini dibagi menjadi empat kelompok dengan metode randomisasi. Kelompok kontrol negatif (NC) mendapatkan injeksi normal saline 0.9% 1cc. Kontrol positif (PC) hanya mendapatkan cisplatin 5 mg/kgBB. Kelompok perlakuan pertama (P1) mendapatkan cisplatin 5 mg/kgBB dan tambahan vitamin E 50 mg/kgBB selama 7 minggu melalui sonde. Kelompok perlakuan kedua (P2) mendapatkan cisplatin 5 mg/kgBB dan tambahan vitamin E 200 mg/kgBB selama 7 minggu melalui sonde. Pada akhir minggu ke-7, dilakukan orkidektomi bilateral untuk pemeriksaan histologis sel epitel germinal testis. Pengamatan apoptosis dilakukan dengan cara menghitung banyaknya sel yang mengalami apoptosis pada penampang sayatan melintang dari tubulus seminiferous yang memberikan reaksi positif terhadap pewarnaan apoptag, dengan menggunakan mikroskop cahaya perbesaran 400x. Pada penelitian ini data dianalisis dengan menggunakan uji One Way ANOVA dan uji post hoc least significant different (LSD). Data dinyatakan berbeda signifikan jika nilai $p < 0.05$. **Hasil:** Pada penelitian ini vitamin E memberikan efek protektif terhadap tikus yang terpapar cisplatin. Pada penelitian ini pemberian vitamin E pada kelompok yang mendapat dosis 50 mg/kgBB (P1) dan 200 mg/kgBB (P2) mampu memberikan proteksi terhadap sel germinal testis dibandingkan dengan kelompok yang mendapat cisplatin. Pada penelitian ini efek protektif vitamin E yang optimal ditunjukkan pada dosis 200 mg/kgBB. **Simpulan:** Vitamin E memberikan efek protektif pada penurunan jumlah apoptosis sel yang disebabkan oleh karena pemberian cisplatin. Efek protektif dari vitamin E ini bergantung pada dosis yang diberikan.

Kata Kunci: Apoptosis, cisplatin, vitamin E.

Correspondence: Achmad Nugroho; c/o: Department of Urology, Faculty of Medicine/Universitas Airlangga, Soetomo General Hospital, Surabaya. Jl. Mayjen. Prof. Dr. Moestopo 6-8 Surabaya 60286. Phone: +62 31 5501318; Fax: +62 31 5024971. Mobile phone: 081226139185. Email: nugrehe@yahoo.com.

INTRODUCTION

There were 14.1 million of new cases of cancer with 8.2 million cancer-related diseases worldwide. It is estimated that 70% of cancer death occurred in a developed country.¹ Israel is the country with the highest incidence rate of 4.9 per 100.000. In Indonesia, the incidence rate is 1.4 per 100.000 population.²

The protocol for testicular tumor (Testicular Germ Cells Tumor (TGCT)) treatment including surgery, chemotherapy, and radiation. Cis-diamine-dichloroplatinum (II) (cisplatin) is a chemotherapy agent that used to treat TGCT.³ Besides having a therapeutic effect on TGCT, cisplatin also affects testicular germ cells through the process of apoptosis resulting in oligozoospermia and azoospermia. Testicular tissue is one of the tissues that are sensitive to ROS free radicals, by binding to the cell membrane in the testis lipid peroxidation will occur in these cells which will eventually trigger damage to both apoptosis and necrosis of these cells.⁴ Research conducted by Seaman et al., showed an elevated apoptotic rate possibly reflecting long-term or permanent damage to the seminiferous tubule by cisplatin exposure.³ Gevrek et al., states that cisplatin mainly caused testicular apoptosis through the Cas-3 and Bax apoptotic protein pathways, and therefore, many preservative agents have been used in combination with cisplatin to decrease damage incurred by cisplatin without altering its antitumoral effectiveness.⁵

Vitamin E (α tocopherol) is an antioxidant that works most effectively. Vitamin E acts to protect the biological membrane from damage caused by free radicals. Vitamin E can prevent the lipid peroxide chains process by giving one hydrogen atom from the OH group to the free radical. Vitamin E which has lost one hydrogen atom does not turn into free radicals but becomes less reactive and does not damage the cells. Vitamin E has a role in protecting biological membranes from damage caused by free radicals. Vitamin E will also protect unsaturated fatty acids in the phospholipid membrane.⁶

OBJECTIVE

The aim of this study to determine the differences of germinal epithelial testicular cell apoptosis in white Sprague Dawley strain rat that received a combination of cisplatin and vitamin E

compared to Sprague Dawley strain rat that received cisplatin only.

MATERIAL & METHODS

The experimental animal in this study was the Sprague Dawley white rat, with age 10-12 weeks, 200-300 grams of body weight, and healthy, that was obtained from a breeding laboratory at the Faculty of Veterinary Medicine, Universitas Airlangga Surabaya. The adaptation process in the cage/research environment was carried out for 2 weeks with a 12-hour light cycle. The sample was randomized into 4 groups, 6 experimental animals in each group and there was a control group as a comparison. Group 1 (NC) was given an injection of 1 cc 0.9% normal saline intraperitoneally as a placebo, group 2 (PC) was given 5 mg/kgBW cisplatin intraperitoneally, group 3 (P1) was given cisplatin injection 5 mg/kgBW intraperitoneally + vitamin E 50 mg/kgBW by gavage and group 4 (P2) was given cisplatin injection 5 mg/kgBW intraperitoneally + vitamin E 200 mg/kgBW by gavage. Vitamin E was given 3 weeks before up to 4 weeks after cisplatin injection. Observation of the germinal epithelial cells apoptosis was carried out by calculating the number of germinal epithelial cells apoptosis in the cross-section of the transverse incision of the seminiferous tubule which gave a positive reaction to the apoptag staining, using a 400x magnification light microscope. The research design used was an experimental study with post-test only control group design. Orchidectomy in both the positive and negative control groups was carried out by rats positioned supine in 75 mg/KgBW of intraperitoneal ketamine anesthesia, scrotum skin incision until the testicles and funiculus were clear, funiculus in the skin at 2 adjacent and cut places including, proximal pieces tied with thread silk 3-0, clamps removed and testicular samples then taken and immediately fixed using ph-buffer formalin 7.4. Within 1 hour after the testicular sample was taken, it will be processed for examination. All actions were carried out using aseptic methods.

Germinal epithelial cell apoptosis was determined by DNA fragmentation on the cell nucleus, using tunnel assay method with Apoptotag® reagent, BioVision, San Fransisco, US. The principle of this method was the combination of molecular reaction and immunohistochemistry, with the molecular reaction is exhibited by the binding of DNA molecular fragment, mediated by terminal

enzyme deoxynucleotida transferase (TdT). Whereas immunohistochemistry was marked with antigen-antibody and a chemical reaction which referred to the reaction between substrate and enzyme. Germinal epithelial cell determination was done with counting the amount of germinal epithelial cell apoptosis on cross-sectional preparations from seminiferous tubule which showed a positive reaction to apoptag dye, using a light microscope with magnification 400x, which was confirmed earlier at 1000x magnification. Cells that experience apoptosis will be seen in blackish brown essence, while cells that did not experience apoptosis essentially did not give a color reaction.

RESULTS

The characteristics of the subject of this study are shown in table 1.

Based on a statistical test using the Shapiro-

Wilk method it can be concluded that apoptosis data in every group was normally distributed with a value of $p > 0.05$. Therefore, data were analyzed using One-way ANOVA test. From the data analysis, it was found that there was a significant difference in germinal epithelial cell apoptosis with p -value < 0.05 . Because of the variance data were homogenous, post hoc LSD was done to determine the difference in each group.

Based on descriptive data (Table 2) it is known that the cisplatin and vitamin E 200 mg/kgBW group a lower number of apoptosis compared to the cisplatin and vitamin E 50 mg/kgBW (Fig. 1).

Based on post hoc LSD data analysis, there was a significant difference between the positive control group compared to the negative control group with a value of $p < 0.05$ (Table 3). Therefore, in this study, it was proven that cisplatin could increase the apoptosis of testicular epithelial germ cells.

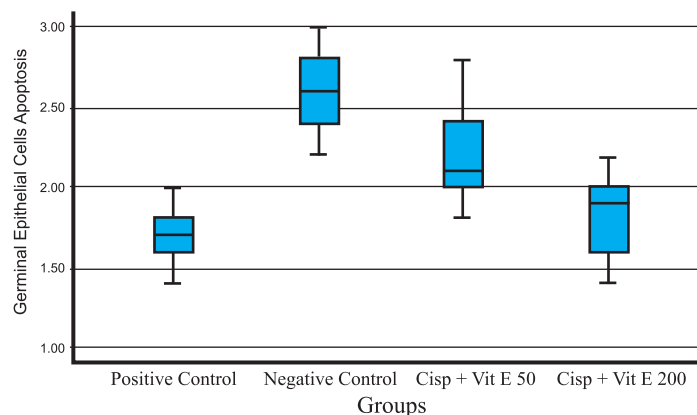
Table 1. Characteristics of the subject of research.

Body weight (gram)	Median (Min -Max)	Mean \pm SD	p-value
Negative Control (NC)	250 (220-270)	248.33 \pm 18.34	0.57 ^a
Positive Control 9PC)	250 (220-280)	252.50 \pm 23.18	
Cisplatin + Vit E 50 mg/kgBW (P1)	245 (220-290)	249.17 \pm 30.07	
Cisplatin + Vit E 200 mg/kgBW (P2)	275 (210-280)	263.33 \pm 27.33	

a: Kruskal-Wallis test

Table 2. Comparison of germinal cell apoptosis in each group.

Group	N	Mean \pm SD	p
Negative Control	6	1.70 \pm 0.21	0.000*
Positive Control	6	2.60 \pm 0.28	
Cisplatin + Vit E 50 mg/kgBW (P1)	6	2.20 \pm 0.36	
Cisplatin + Vit E 200 mg/kgBW (P2)	6	1.83 \pm 0.29	

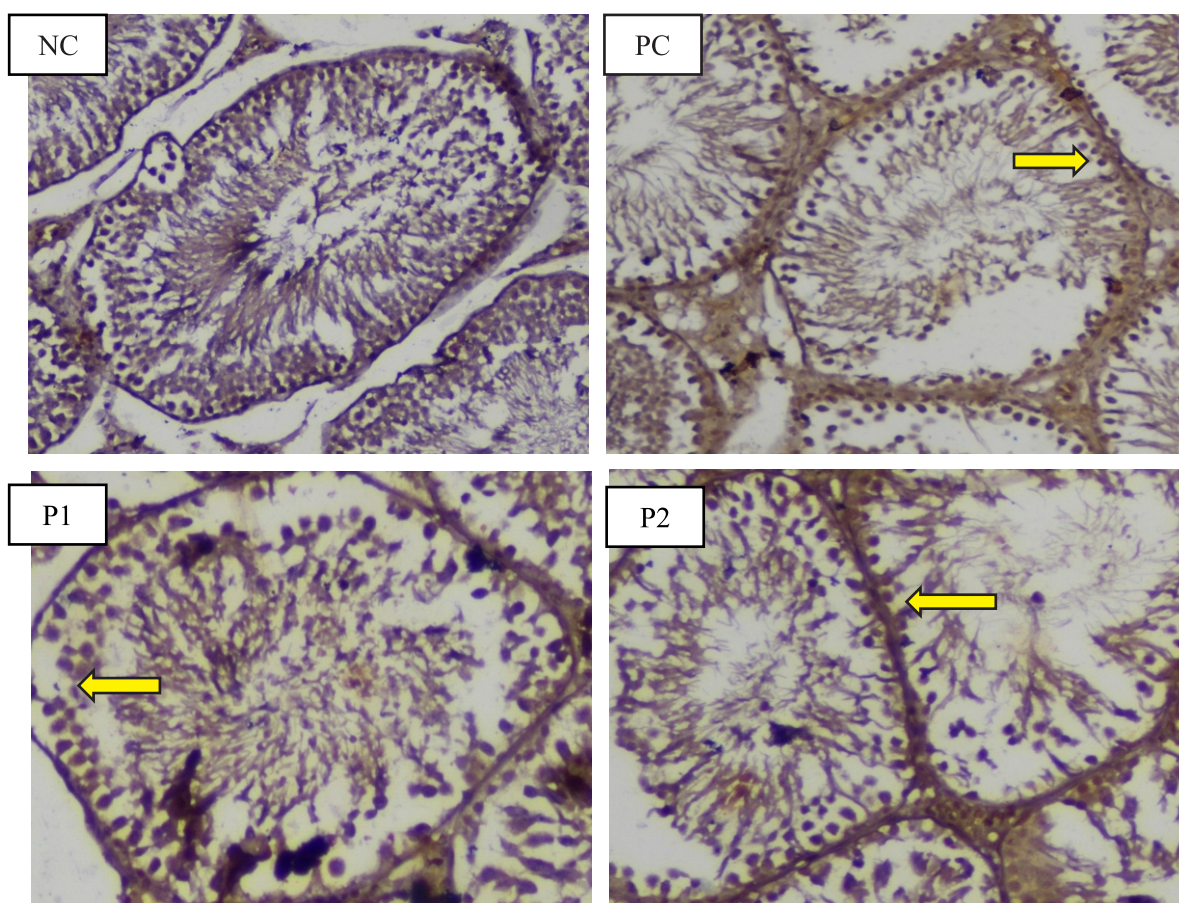


* : statistically significance

Figure 1. Comparison of apoptosis of testicular epithelial germ cells in each group.

Table 3. Post Hoc LSD analysis compared apoptosis in each group.

Groups	Mean differences	95% CI		p-value
		Lower Bound	Upper Bound	
Negative vs Positive Control	-0.90	-1.25	-0.55	0.000*
Negative Control vs Cisplatin + Vit E 50 mg/kgBW	-0.50	-0.85	-0.15	0.007*
Negative Control vs Cisplatin + Vit E 200 mg/kgBW	-0.13	-0.48	0.22	0.437
Positive control vs Cisplatin + Vit E 50 mg/kgBW	0.40	0.049	0.75	0.027*
Positive control vs Cisplatin + Vit E 200 mg/kgBW	0.77	0.42	1.12	0.000*
Cisplatin + Vit E 50 mg/kgBW vs Cisplatin + Vit E 200 mg/kgBW	0.37	0.016	0.72	0.041*

**Figure 2.** Detection of apoptosis by TUNEL staining (indicated by arrows). Cross-sectional microscopy of the seminiferous tubules in rats group: A. Negative control, B. Cisplatin only group, C. Cisplatin + Vitamin E 50 mg/kgBW group, D. Cisplatin + Vitamin E 200 mg/kgBW x 400.

There was a significant difference in the apoptosis of germinal epithelial cells in the cisplatin + vitamin E 50 mg/kgBW compared to the cisplatin group with a p-value <0.05 (Table 3). Likewise, in the cisplatin + vitamin E 200 mg/kgBW, there was a significant difference when compared to the cisplatin group ($p < 0.05$). So that both vitamin E 50 mg/kgBW and vitamin E 200 mg/kgBW can indeed

provide a protective effect on apoptosis of testicular germ cells.

However, when compared between vitamin E 50 mg and vitamin E 200 mg there was a significant difference ($p < 0.05$).

It can be seen that the group that received a cisplatin and vitamin E 200 mg/kgBW had a lower number of apoptosis compared to the group that

received a cisplatin and vitamin E 50 mg/kgBW ($p < 0.05$). Therefore, the administration of vitamin E 200 mg/kgBW had a significant effect in preventing an increase in the number of apoptosis in the positive control group receiving cisplatin injection and has no significant difference compared to negative controls. In this study, it was seen that the dose that had superior effectiveness was vitamin E 200 mg/kgBW.

DISCUSSION

Cisplatin is widely used in the treatment of various types of cancers including testicular, lung, ovarian, bulbous and lymphoma cancers.⁷ Cisplatin therapy shows satisfactory results in testicular germ cell tumors.⁸ Cisplatin has a toxic effect in addition to its positive effects. The therapeutic dose given can change according to the patient's conditions. The success of cancer chemotherapy depends on the ability to minimize its toxicity. Side effects include nausea, vomiting, myelosuppression, immunosuppression, nephrotoxic, neurotoxic, and ototoxic.^{9,10}

Previous studies have assessed the side effects of cisplatin in the process of spermatogenesis in rats.¹¹ Cisplatin reduced the number of spermatogonia, sertoli cells and leydig cells on observation for 7 weeks. The administration of vitamin E 200 mg/kgBW has a protective effect on the decrease in the number of spermatogonia, sertoli cells and leydig cells due to exposure to cisplatin 5 mg/kg.¹²

Cisplatin has an anti-cancer effect through its interaction with DNA and induces apoptosis.¹³ Toxic biotransformation product is a monohydrate complex (MHC) formed from the cisplatin hydrolysis process. Cisplatin causes cell damage due to the radical oxygen species (ROS) that it produces. Damage to healthy cells around the tumor occurs because certain amounts of ROS are needed in cell metabolism, the amount increases, and endogenous antioxidants are not able to inhibit this increase. ROS compounds include NO, O₂ o⁻, ONOO⁻, RSNOS, and H₂O₂. Accumulation of ROS will release cytochrome-c from mitochondria through activation of the c-Jun-N-terminal kinase (JNK) and p38MAPK. Cytochrome-c will then activate caspase-8, -9, and -3 (intrinsic pathway apoptosis), thus causing apoptosis.¹⁴

Various agents from outside the body can induce apoptosis, such as chemotherapy drug and the radiation. Cisplatin has been widely studied both in

normal or tumor cells including testicular tumor cells. Apoptosis of cisplatin-induced germ cells occurs in the seminiferous tubules of rat testicles. Apoptosis induced by cisplatin was found in spermatogonia, spermatocytes, and spermatids on mice.⁸

Apoptosis is a process of cell death that occurs as a normal and controlled part of an organism's developments. It is characterized by a swollen membrane, cytoplasmic condensation and cell nucleus, and core DNA damage.¹⁵ As in previous studies on mice by Zhang et. al cisplatin treatment induced a significant increase of germ cell apoptosis in the mouse testes on 7 days observations. During the normal process of spermatogenesis in adults, apoptosis may occurs in different phases of germinal cell growth.⁸ According to Lu Cai et al., spontaneous apoptosis in rat testicles can be observed morphologically. Low apoptosis rates in experimental animals occur at the stages of premeiosis spermatogonia and spermatocytes as a self-defense mechanism so that abnormal cells will experience apoptosis to prevent their abnormality being lowered to the next living cell.¹⁵

Intraperitoneal administration of cisplatin 5mg/kgBW significantly increased apoptosis ($p < 0.05$). This is consistent with the research conducted by Daryosh et al., whose states that cisplatin causes the apoptosis of germinal epithelial cells of the testis.⁷ One mechanism for cell damage in patients undergoing chemotherapy is apoptosis. Cisplatin creating adduction, cross-linking, and breaking of chains that inhibit DNA replication. This irreversible DNA damage causes activation of the apoptotic pathway.^{8,16} Adverse side effects after cisplatin therapy are mainly related to spermatogenic damage, decreased testicular volume, body weight, and germinal cell apoptosis after cisplatin administration.¹⁷ Cisplatin has been proved to induce testicular disintegration which causes apoptosis of germinal cells, and abnormalities in Leydig cells.^{18,19} The toxicity of cisplatin due to rigidification of the membrane, lipids peroxidation, and oxidative stress in mice and reduction of antioxidant.²⁰

There was a significant difference in the number of apoptosis of germinal epithelial germ cells in the group receiving cisplatin 5 mg/kg + vitamin E 50 mg/kgBW compared to the group given cisplatin alone with a p-value < 0.05 (Table 3). Likewise, in the cisplatin group 5 mg/kgBW + vitamin E 200 mg/kgBW there was a lower apoptosis when compared with the group exposed to cisplatin

($p < 0.05$). So that both vitamin E 50 mg/kgBW and vitamin E 200 mg/kgBW can indeed provide a protective effect on apoptosis of testicular germ cells. There are two pathways for induction of apoptosis, the first induction in cells in the G2/M phase causes the death of the cell, while in the other pathway is cycle-independent cells and occurs rapidly. The results showed that apoptosis of germinal cells induced by cisplatin in rat testicles occurred through a combination of these two pathways, cell apoptosis due to hyperthermia, chemical agents also chemotherapy treatment. There have been several studies on cisplatin-induced apoptotic in vivo by chemical agents, but the apoptosis of the germ cell was only observed in human.⁸ Therefore, there are several substances that can be used in combination with cisplatin to reduce the damage caused by cisplatin without reducing the antitumor effect.⁵ Antioxidants such as vitamin C, vitamin E (α tocopherol), melatonin, and lycopene are already been studied and shows a protective effect against cisplatin-induced toxicity.²¹⁻²²

Vitamin E contains tocopherol, tocotrienol, and anti-free radicals, and reduces its toxicity to kidneys and endothelial cells. Vitamin E activity is shown by several side-chain isomers and methylated analogs of tocopherol and tocotrienol. These mono- (d-tocopherol), di- (β - and γ -tocopherols) and tri- (α -tocopherol) methyl derivatives differ in vitamin E activity. Some of the vitamers E common in foods (β - and γ -tocopherol, the tocotrienols) have little biological activity. The most biopotent vitamin E-vitamer of greatest interest in nutrition is α -tocopherol, which occurs naturally as the RRR stereoisomer [(RRR)- α -tocopherol].²³ Vitamin E protects unsaturated fatty acids from cell membranes from damage caused by free radicals by inhibiting lipid peroxidase reactions. Kalkanis et al, showed that supplementation of vitamin E could reduce the toxicity caused by cisplatin in mice. Supplementation of combination vitamin E and dexamethasone was very effective in reducing the toxicity of cisplatin.⁵

The electron derivative of vitamin E, the tocopheroxyl radical, which is an inherent part of each antioxidant reaction based on vitamin E, has shown its function as a protection against genotoxicity based on its ability to decide radical chain reactions.²⁴

In this study, it can be seen based on descriptive data (Table 2) that the group that received the injection of cisplatin and vitamin E 50 mg/kgBW

had a lower number of apoptosis compared to the group receiving cisplatin injection $p < 0.05$ (Table 3). In the group that received an injection of cisplatin and vitamin E 200 mg/kgBW had a lower number of apoptosis compared to the group that received an injection of cisplatin $p < 0.05$. Based on the post hoc test there were significant differences between the number of apoptosis in the group that received an injection of cisplatin and vitamin E 200 mg/kgBW compared to the injection group of cisplatin and vitamin E 50 mg/kgBW with a value of $p < 0.05$. There was no significant difference between germinal cell apoptosis in the cisplatin group 5 mg/kgBW + vitamin E 200 mg/kgBW and the negative control group with a value of $p > 0.05$. This showed that the administration of vitamin E 200 mg/kgBW had a significant effect in reducing the number of apoptosis in the group receiving cisplatin injection and its effectiveness was superior compared to the administration of vitamin E 50 mg/kgBW. This is in accordance with the study by Fikret et al., which showed that cisplatin causes testicular apoptosis through the apoptotic protein pathway Cas-3 and Bax and decreases Bcl-2.5 Supplementation with vitamin E is expected to reduce the amount of apoptosis due to cisplatin the faster recovery of the testes leads to the normal process of spermatogenesis.

CONCLUSION

Vitamin E (α tocopherol) provides a protective effect on decreasing the amount of apoptosis due to the cisplatin exposure 5 mg/kg, the effectiveness of vitamin E depends on the dose given, i.e. dose of 200 mg/kgBW showed a superior result than 50 mg/kgBW.

REFERENCES

1. Ferlay J, Soerjomataram I, Dikshit R, Eser S, Mathers C, Rebelo M, et al. Cancer incidence and mortality worldwide: Sources, methods and major patterns in GLOBOCAN 2012. *Int J Cancer*. 2015; 136(5): E359-86.
2. Sadeghi M, Ghoncheh M, Mohammadian-Hafshejani A, Gandomani HS, Rafiemanesh H, Salehiniya H. Incidence and mortality of testicular cancer and relationships with development in Asia. *Asian Pac J Cancer Prev*. 2016; 17(9): 4251-7.
3. Seaman F, Sawhney P, Giammona CJ, Richburg JH. Cisplatin-induced pulse of germ cell apoptosis precedes long-term elevated apoptotic rates in C57/BL/6 mouse testis. *Apoptosis*. 2003; 8(1): 101-8.

4. Agarwal A, Makker K, Sharma R. Clinical relevance of oxidative stress in male factor infertility: An update. *Am J Reprod Immunol*. 2008; 59(1): 2-11.
5. Gevrek F, Erdemir F. Investigation of the effects of curcumin, vitamin E and their combination in cisplatin-induced testicular apoptosis using immunohistochemical technique. *Türk Üroloji Dergisi/Turkish J Urol*. Jan 2018; 44(1): 16-23.
6. Uzunhisarcikli M, Kalender Y. Protective effects of vitamins C and E against hepatotoxicity induced by methyl parathion in rats. *Ecotoxicol Environ Saf*. 2011; 74(7): 2112-8.
7. Mohammadnejad D, Abedelahi A, Soleimani-rad J, Mohammadi-Roshandeh A, Rashtbar M, Azami A. Degenerative effect of cisplatin on testicular germinal epithelium. *Adv Pharm Bull*. 2012; 2(2): 173-7.
8. X Zhang, N Yamamoto, S Soramoto. Cisplatin-induced germ cell apoptosis in mouse testes. *Arch Androl*. 2001; 46(1): 43-9.
9. Desoize B, Madoulet C. Particular aspects of platinum compounds used at present in cancer treatment. *Critical Reviews in Oncology/Hematology*. 2002; 42: 317-25.
10. Shah N, Dizon DS. New-generation platinum agents for solid tumors. *Futur Oncol*. 2009; 5(1): 33-42.
11. Türk G, Atessahin A, Sönmez M, Çeribasi AO, Yüce A. Improvement of cisplatin-induced injuries to sperm quality, the oxidant-antioxidant system, and the histologic structure of the rat testis by ellagic acid. *Fertil Steril*; 2008.
12. Rahmad Krismantoro, Fikri Rizaldi, I Ketut Sudiana, Doddy M Soebadi. Effect of vitamin e (α tocopherol) administration to prevent spermatogonium, sertoli, and leydig cell damages on rats testis (wistar strain) after cisplatin treatment; 2017
13. Cepeda V, Fuertes MA, Castilla J, Alonso C, Quevedo C, Pérez JM. Biochemical mechanisms of cisplatin cytotoxicity. *Anticancer Agents Med Chem*. 2007; 7(1): 3-18.
14. Barabas K, Milner R, Lurie D, Adin C. Cisplatin: A review of toxicities and therapeutic applications. *Veterinary and Comparative Oncology*. 2008; 6:1-18.
15. Cai L, Hales BF, Robaire B. Induction of apoptosis in the germ cells of adult male rats after exposure to cyclophosphamide. *Biol Reprod*; 1997.
16. Kaminski R, Darbinyan A, Merabova N, Deshmane SL, White MK, Khalili K. Protective role of Pur? to cisplatin. *Cancer Biol Ther*; 2008.
17. Anand H, Misro MM, Sharma SB, Prakash S. Protective effects of eugenia jambolana extract versus N-acetyl cysteine against cisplatin-induced damage in rat testis. *Andrologia*; 2015.
18. Meistrich ML, Finch M, Cunha MF, Hacker U, Au WW. Damaging effects of fourteen chemotherapeutic drugs on mouse testis cells damaging effects of fourteen chemotherapeutic drugs on mouse testis. Jan 1982; 42: 122-31.
19. Cherry SM, Hunt PA, Hassold TJ. Cisplatin disrupts mammalian spermatogenesis, but does not affect recombination or chromosome segregation. *Mutat Res - Genet Toxicol Environ Mutagen*. Dec 2004; 564(2): 115-28.
20. Martins N, Santos N, Curti C, Bianchi L, Santos A. Cisplatin induces mitochondrial oxidative stress with resultant energetic metabolism impairment, membrane rigidification and apoptosis in rat liver. *J Appl Toxicol*. October 2008; 28: 608-20.
21. Atessahin A, Sanna E, Türk G, Çeribasi AO, Yilmaz S, Yüce A, et al. Chemoprotective effect of melatonin against cisplatin-induced testicular toxicity in rats. *J Pineal Res*; 2006.
22. Atessahin A, Karahan I, Türk G, Gür S, Yilmaz S, Çeribasi AO. Protective role of lycopene on cisplatin-induced changes in sperm characteristics, testicular damage and oxidative stress in rats. *Reprod Toxicol*. 2006; 21(1): 42-7.
23. Combs Jr GF. Vitamin fundamental aspect in nutrition, 3rd Ed. New York: Elsevier; 2008.
24. Ingold KU, Webb AC, Witter D, Burton GW, Metcalfe TA, Muller DPR. Vitamin E remains the major lipid-soluble, chain-breaking antioxidant in human plasma even in individuals suffering severe vitamin E deficiency. *Arch Biochem Biophys*; 1987.