

# EFFECT OF TESTOSTERONE DEPRIVATION ON SMOOTH MUSCLE-COLLAGEN RATIO IN BLADDER WALL OF WISTAR RATS

<sup>1</sup>Wendi Rachman, <sup>1</sup>Aaron Tigor Sihombing, <sup>1</sup>Suwandi Sugandi, <sup>2</sup>Bethy S. Hernowo.

<sup>1</sup>Department of Urology, Faculty of Medicine/Padjadjaran University, Hasan Sadikin Hospital, Bandung.

<sup>2</sup>Department of Pathology, Faculty of Medicine/Padjadjaran University, Hasan Sadikin Hospital, Bandung.

## ABSTRACT

**Objective:** To evaluate the smooth muscle-collagen fibers ratio in the bladder wall of castrated male wistar rats.

**Material & method:** Sixteen wistar rats were equally assigned to castrated group ( $n = 8$ ) and sham group ( $n = 8$ ). All wistar rats were subjected to a one-week acclimatization period before undergoing treatment. After 60 days, cystectomy was performed in all rats in both groups and subsequent specimens of the bladder were taken to semi-quantitative pathology analysis using haematoxylin eosin (HE) staining under Olympus CX20<sup>®</sup> microscope by a uropathologist. Results were then grouped into parametric data and analyzed using independent T-test. **Results:** Smooth muscle fibers were significantly lower in the castrated group  $0,615 \pm 0,13$  ( $p = 0,01$ ). There was higher amount of collagen fibers in the castrated group  $0,385 \pm 0,18$  ( $p = 0,04$ ). Smooth muscle to collagen ratio in the castrated group was also significantly lower compared to the control group  $1,597 \pm 0,25$  ( $p = 0,03$ ). **Conclusion:** Testosterone deprivation significantly reduces the smooth muscle and smooth muscle to collagen fibers ratio in bladder wall of castrated rats.

**Keywords:** Testosterone deprivation, smooth muscle, collagen.

Correspondence: Wendi Rachman, c/o: Department of Urology, Faculty of Medicine/Padjadjaran University, Hasan Sadikin Hospital, Jl. Pasteur No. 38, Bandung 40161. Phone: 022-2039141. E-mail: wenditea@yahoo.com

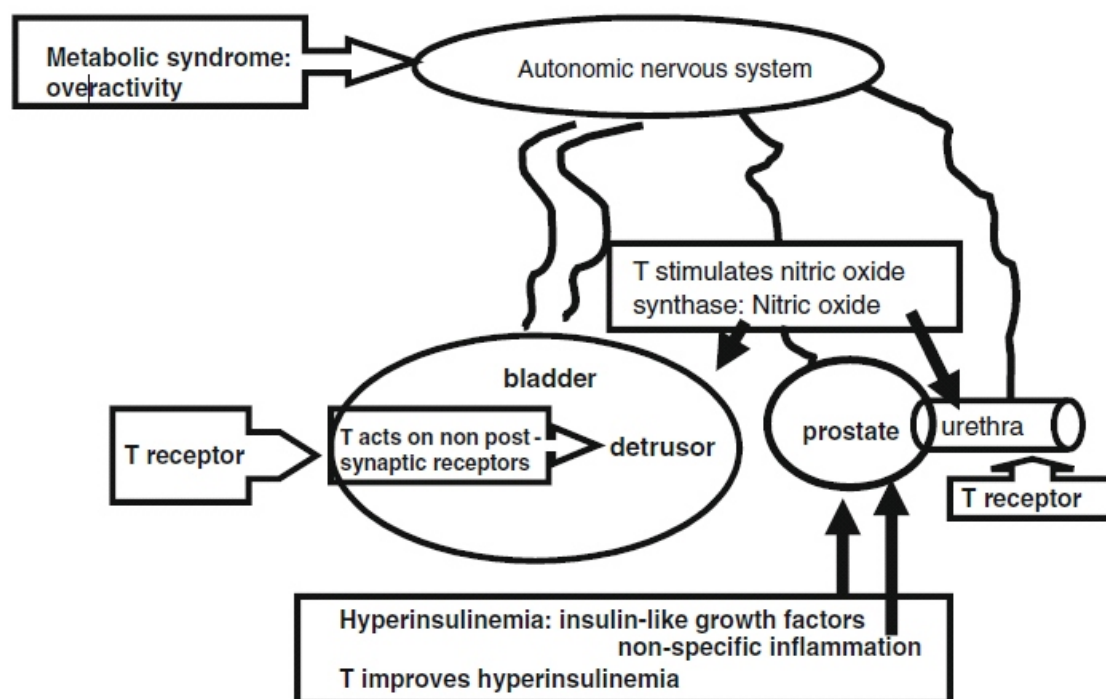
## INTRODUCTION

The effect of testosterone on the bladder remains unclear. There is ongoing debate on the precise mechanism and impact of testosterone on the bladder. Androgen receptor exists on bladder, urethral epithelium and smooth muscle of the bladder wall. The controversy especially affects the aging male population with testosterone deficiency known as late onset hypogonadism (LOH), with problems such as metabolic syndrome, overactive bladder (OAB) and sexual dysfunction.<sup>1,2</sup>

Incidence of OAB is 12 - 45% in LOH patients, and testosterone deficiency might induce or aggravate OAB. Numerous publications had been dedicated to answer part of the questions that persistent LUTS following TURP for BPH is merely unveiling underlying OAB. Several studies has elaborated that OAB might be the result of

testosterone-estrogen imbalance with inclination toward relative hyperestrogenism. Deficiency of testosterone is noted to promote degenerative effects on bladder wall. The process was found to be up-regulated by the RhoA/ROCK pathway. Some authors stated that testosterone therapy alone was effective in improving bladder function, relieving LUTS, and reverse bladder atrophy.<sup>3-6</sup>

Plausible explanations for these findings include the existence of androgen receptors on the bladder, urothelium, and smooth muscle of bladder wall thus testosterone deficiency acts on autonomic nervous system by inducing hyperactive reflex response. Furthermore, testosterone was postulated to exert relaxation of bladder wall through promoting production of nitric oxide. Testosterone is also known to suppress detrusor activity through a postsynaptic non-genomic receptor (Figure 1).<sup>3,4</sup>



**Figure 1.** Potential sites of action of testosterone on the urinary tract.<sup>4</sup>

Nitric oxide (NO) acting as a non-adrenergic non-cholinergic neurotransmitter is not only present in genital structures but also in the urinary tract and exerts a smooth muscle relaxing effect in both animals and humans. A study in humans indicated that NO is involved in several other functions of the human urogenital tract. In humans, 72 - 96% of neurons in the bladder wall appear to contain nitric oxide synthase. Nitric oxide synthase-immunoreactive nerve terminals provide moderate innervation to the detrusor muscle of the bladder body, and a denser innervation to the urethral muscle. Nitric oxide may be an inhibitory transmitter involved in the relaxation of the bladder neck. Cyclic nucleotides are important secondary messengers of nitric oxide involved in modulating the contractility of various smooth muscles.<sup>4</sup>

## OBJECTIVE

To evaluate the smooth muscle-collagen fibers ratio in the bladder wall of castrated male wistar.

## MATERIAL & METHOD

The study was conducted from May-August 2010. Sixteen adult wistar rats, age 8 weeks, weight 300-400 gr, were equally assigned to sham group (n = 8) or treatment (castrated n = 8) group. Sample size was determined using formula for 2 independent sample.

Each group was placed in the same cage, and subjected to a seven-day acclimatization period before undergoing treatment. The treatment group underwent surgical castration. After 60 days, cystectomy was performed in all rats in both groups by lower midline laparotomy. The rats were anesthetized with intraperitoneal injection of ketamine (50 - 100 mg/kg).<sup>5,7,8</sup> Subsequent specimens of the bladder was stained with haematoxylin eosin (HE) and underwent semi-quantitative pathological analysis using Olympus CX 20 microscope by a single experienced pathologist. Results were then grouped into parametric data and analyzed using Independent T-test with p value < 0,05 considered significant.

## RESULTS

At the beginning of the experiment, no significant differences in mean body weight were observed among the two groups (Table 1),  $383,45 \pm 12,33$  gr in the control group and  $318,26 \pm 12,33$  gr in the castrated group ( $p=0,08$ ).

The size of subsequent specimen also has no significant differences between the two groups, shown in table 2. Smooth muscle fiber was significantly lower in the castrated group  $0,615 \pm 0,13$  compare with  $0,725 \pm 0,13$  in the control group ( $p = 0,01$ ), and there was

more collagen fiber in the castrated group  $0,385 \pm 0,18$  compared to  $0,275 \pm 0,18$  in the control group ( $p = 0,04$ ). There was also significantly lower smooth muscle to collagen ratio in the castrated group  $1,597 \pm 0,25$  compared to  $2,636 \pm 0,25$  in the control group ( $p = 0,03$ ).

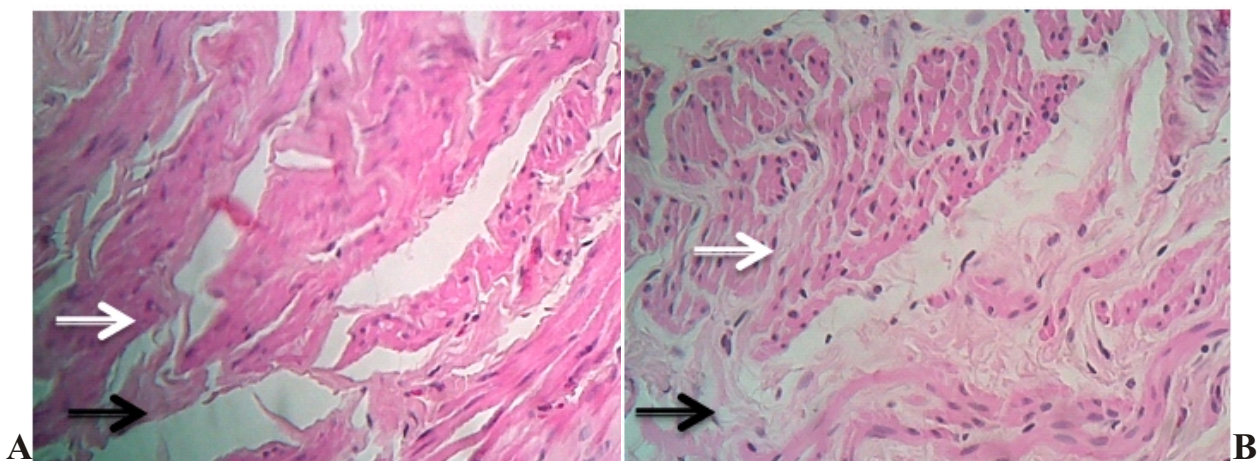
As shown in Figure 2, there were decreased smooth muscle (white arrow) and increased collagen fibers (black arrow) in the castrated group compared to the control group. The nuclei showed presence of smooth muscle, those differing from non nucleated collagen fibers.

**Table 1.** The mean body weight both groups compare.

Wistar rats	Control	Castrated	p
Weight	$383,45 \pm 12,33$ gr	$318,26 \pm 12,33$ gr	0,08

**Table 2.** The mean smooth muscle, collagen, and smooth muscle-collagen ratio.

Wistar rats	Control	Castrated	p
Specimen size	$108,43 \pm 5,24$ mm <sup>2</sup>	$105,18 \pm 5,24$ mm <sup>2</sup>	0,12
Muscle	$0,725 \pm 0,13$	$0,615 \pm 0,13$	0,01
Collagen	$0,275 \pm 0,182,6$	$0,385 \pm 0,18$	0,04
Muscle-collagen	$36 \pm 0,25$	$1,597 \pm 0,25$	0,003



**Figure 2.** HE staining of wistar bladder. White arrow show smooth muscle and black arrow show collagen fibers. (A) Control group, (B) castrated group.

## DISCUSSION

The influence of sex hormones on the lower urinary tract is of interest. Male and female hormones together regulate the development and function of lower urinary tract muscles in male rats.<sup>9</sup> In humans, total plasma testosterone declines by approximately 1% per year on an average from the age of around 40 years.<sup>3,8</sup> Due to concomitant increase of sex hormone binding globulin, free testosterone levels decrease even more steeply from this age. Unbound testosterone also decreases with aging.<sup>10</sup> However, its effects on lower urinary tract functions have not been fully characterized.<sup>1,8</sup> In the present study on its effects on elderly male rats, they reported average plasma testosterone levels as  $2,34 \pm 0,21$  ng/mL in 12-month-old rats and  $0,78 \pm 0,17$  ng/mL in 24-month-old rats.<sup>11</sup> Another study showed average plasma testosterone levels of  $2,61 \pm 0,69$  ng/mL in treated rats, and  $0,83 \pm 0,41$  ng/mL in control rats.<sup>8</sup>

The difference in mean body weight was not significant between both groups. The mean bladder weight was significantly greater in the treated group than the control group. Histologically, the amount of muscle tissues was significantly lower in the castrated group, and the ratio of smooth muscle-to-collagen fibers area was significantly lower in the castrated group than in the control group.<sup>1,7,8</sup> Lower amount of smooth muscle tissue in castrated group may be caused by upregulation of RhoA/ROCK pathway, that initiate smooth muscle degeneration by destruction of actin-myosin structure.<sup>3-6</sup>

The lower ratio of smooth muscle-to-collagen tissue area appeared to decrease detrusor pressure, and bladder capacity decreases with bladder compliance.<sup>1,2,4,7,8,11</sup> In the presence of testosterone replacement, elderly male rats showed increases in bladder smooth muscles, ratio of smooth muscle area-to-connective tissue area, bladder capacity and detrusor pressure.<sup>8,11</sup>

More studies will be necessary to find out if these changes in the bladder are due to the direct effect of testosterone or the secondary effect of increased urethral resistance. Studies about testosterone,

estrogen, and combinations of both are needed to reveal effective treatment for OAB. However we also have to consider effects of testosterone replacement on the prostate gland.<sup>12</sup>

## CONCLUSION

Testosterone deprivation obviously reduce smooth muscle and of smooth muscle-to-collagen fibers ratio in the bladder wall of castrated wistar rats.

## REFERENCES

1. Tek M, Balli E, Cimen B, Efesoy O, Oguz I, Cayan S. The effect of testosterone replacement therapy on bladder functions and histology in orchidectomized mature rats. *J Urol* 2010; 75 (4): 886-90.
2. Karazindiyanoglu S, Cayan. The effect of testosterone therapy on lower urinary tract symptoms-bladder and sexual functions in men with symptomatic late-onset hypogonadism. *J Aging Male* 2008; 11 (3): 146-9.
3. Chavalmane AK. Sex steroid receptors in male human bladder: Expression and biological function. *J Sex Med* 2010; 20.
4. Yassin AA, El-Sakka A, Saad F, Louis JG, Gooren LJG. Lower urinary-tract symptoms and testosterone in elderly men. *World J Urol* 2008; 26 (4): 359-64.
5. Cayan F, Tek M, Balli E, Oztuna, Karazindiyanoglu S, Cayan S. The effect of testosterone alone and testosterone + estradiol therapy on bladder functions and smooth muscle-collagen content in surgically menopause rats. *J Maturitas* 2008; 60: 248-52.
6. Knutson T, Edlund C, Fall M, Dahlstrand C. BPH with coexisting overactive bladder dysfunction-an everyday urological dilemma. *Neurourol Urodyn* 2001; 20 (3): 2.
7. Morizane S, Toji S, Matsumoto M, Miyagawa I. Effects of testosterone replacement on lower urinary tract functions in elderly male rats. *Yonago Acta Med* 2005; 48: 939.
8. Mucignat-Caretta C, Bondi M, Caretta A. Endocrine status affects bladder size and postvoid residual urinary volume in mice. *Horm Behav* 2004; 46: 11-8.
9. Salmi S, Santti R, Gustafsson J, Makela S. Colocalization of androgen receptor with estrogen receptor  $\beta$  in the lower urinary tract of the male rat. *J Urol* 2001; 166: 6747.

10. Feldman HA, Longcope C, Derby CA, Johannes CB, Araujo AB, Coviello AD, et al. Age trends in the level of serum testosterone and other hormones in middle-aged men: Longitudinal results from the Massachusetts Male Aging Study. *J Clin Endocrinol Metab* 2002; 87: 58998.
11. Sato Y, Shibuya A, Adachi H, Kato R, Horita H, Tsukamoto T. Restoration of sexual behavior and dopaminergic neurotransmission by long term exogenous testosterone replacement in aged male rats. *J Urol* 1998; 160: 15725.
12. Ebert T. Clinical experiences with testosterone therapy: Prostate safety. *Aging Male* 2004; 7: 30411.