

TUBERCULAR TESTICULAR ABSCESS: A CASE REPORT

¹Rocci Jack Parse, ¹Ahmad Agil.

¹ Department of Urology, Faculty of Medicine/Padjadjaran University, Hasan Sadikin Hospital, Bandung.

ABSTRACT

Objective: This study aims to provide fellow physicians a better insight in diagnosing and managing similar cases. **Case(s) Presentation:** A 36 year old male presented to the emergency department with a chief complaint of red, painful, and progressively enlarging swelling of the left scrotal pouch since 1 week ago. The patient had a history of similar complaint and recurrent cloudy urine which were left untreated 1 year before. Based on physical examination and ultrasonography findings, the patient was diagnosed with left scrotal abscess and was treated by incisional drainage of abscess and necrotomy debridement under spinal anesthesia. **Discussion:** Tuberculosis infection of scrotal contents is rare and occurs in approximately 7% of the patients with tuberculosis, although tuberculosis itself is a global epidemic with more than 2 billion of the world population infected. In patients with genital tuberculosis, pulmonary and renal tuberculosis can be documented in 50% and 80-85% respectively. It is often secondary to the pre-existing tuberculosis of the urinary tract, which may be confirmed by the culture of early morning urine specimens. **Conclusion:** Treatment of testicular abscess is administration of appropriate antibiotics according to its causative organism accompanied by surgical drainage. Early diagnosis and prompt treatment of testicular abscess is necessary, since chronic and severe cases, as happened in this patient, usually resulted in nonviable testicular tissue and necessitate orchidectomy. This may be due to cumulative ischemia of the testicles from multiple mechanisms: inflammatory infiltration causing compression of the spermatic cord, thrombosis secondary to venous congestion and/or bacterial exotoxins.

Keywords: Orchidectomy, tuberculosis, tubercular testicular abscess.

ABSTRAK

Tujuan: Penelitian ini bertujuan untuk memberikan wawasan yang lebih baik kepada rekan-rekan dokter dalam mendiagnosis dan menangani kasus serupa. **Presentasi Kasus:** Seorang laki-laki berusia 36 tahun datang ke IGD dengan keluhan utama bengkak merah, nyeri, dan semakin membesar pada kantong skrotum kiri sejak 1 minggu yang lalu. Pasien memiliki riwayat keluhan serupa dan urin keruh berulang yang tidak diobati 1 tahun sebelumnya. Berdasarkan pemeriksaan fisik dan temuan ultrasonografi, pasien didiagnosis dengan abses skrotum kiri dan dirawat dengan drainase insisional abses dan debridement nekrotomi dengan anestesi spinal. **Diskusi:** Infeksi tuberculosis isi skrotum jarang terjadi dan terjadi pada sekitar 7% pasien tuberculosis, meskipun tuberculosis sendiri merupakan epidemi global dengan lebih dari 2 miliar penduduk dunia terinfeksi. Pada pasien dengan tuberculosis genital, tuberculosis paru dan ginjal dapat didokumentasikan pada 50% dan 80-85% masing-masing. Hal ini sering sekunder dari tuberculosis saluran kemih yang sudah ada sebelumnya, yang dapat dikonfirmasi dengan kultur spesimen urin pagi hari. **Simpulan:** Pengobatan abses testis adalah pemberian antibiotik yang tepat sesuai organisme penyebabnya disertai dengan drainase bedah. Diagnosis dini dan pengobatan abses testis yang tepat diperlukan, karena kasus kronis dan berat, seperti yang terjadi pada pasien ini, biasanya mengakibatkan jaringan testis yang tidak dapat hidup dan memerlukan orkidektomi. Ini mungkin karena iskemia kumulatif testis dari beberapa mekanisme: infiltrasi inflamasi yang menyebabkan kompresi korda spermatika, trombosis sekunder akibat kongesti vena dan/atau eksotoksin bakteri.

Kata Kunci: Orkidektomi, tuberculosis, abses testis tuberculosis.

Correspondence: Rocci Jack Parse; c/o: Urology Department, Faculty of Medicine/University of Padjadjaran, Hasan Sadikin General Hospital, Jl. Pasteur No.38, Sukajadi, Bandung, Jawa Barat 40161, Indonesia. Email: roccijackparse@gmail.com.

INTRODUCTION

The testicular abscess is an uncommon disease and is usually preceded by untreated epididymo-orchitis.¹⁻² Descending infection from the

urinary tract, direct extension of infection from neighboring organs, or hematogenous spread of causative organism resulted in this condition. A multitude of organism causing testicular abscess had been identified, namely *Escherichia coli* and

Chlamydia trachomatis which are considered to be the commonest pathogen, and *Mycobacterium tuberculosis* which are usually only found in the immunocompromised patient.²

Tuberculosis infection of the scrotum is rare and occurs in approximately 7% of the patients with tuberculosis.^{3,4} Treatment of testicular abscess is administration of appropriate antibiotics according to its causative organism accompanied by surgical drainage.² Early diagnosis and prompt treatment of testicular abscess is necessary, as chronic cases usually resulted in nonviable testicular tissue and necessitate orchidectomy.² This case report described a rare case of tuberculosis testicular abscess in order to provide a better insight in diagnosing and managing similar cases.

CASE(S) PRESENTATION

A 36 year old male came to the emergency department with a chief complaint of painful swelling of the left scrotal pouch which had been presented since 1 week before. The swollen scrotum was reported to be getting progressively bigger and was accompanied by redness and tenderness. The patient also complained of intermittent fever. There were no history of weakness, nausea, vomiting, swelling of both legs, shortness of breath, and decreased consciousness. There was no sign of bowel obstruction. His urine appearance was reported to be clear-yellowish colored with daily production around 1500 cc per 24 hours.

Further history taking revealed that the patient had a previous history of similar complaint 1 year ago, he reported having lumps on both scrotal sacs which then burst spontaneously and followed by intermittent episodes of pus discharge. The patient

did not seek any treatment for this episode because he felt any improvement. The patient also had a history of recurrent cloudy urine since 1 year ago but denied any experience of dysuria, urethral discharge, venereal disease or obstructed urine outflow.

He also denied any history of urethral catheterization or sexual activity. There was no history of passing sand-like sediment in urine, urinary stones, or bloody urine. There was no relevant past surgical or family history. The patient denied past diagnosis of hypertension and diabetes mellitus. He denied any contact with individuals with active pulmonary tuberculosis or previous testing for tuberculosis infection.

Upon physical examination on admission, the patient alert, and vital signs were within normal limits. The abdomen was soft, no tenderness, and non-distended, and bowel sounds within normal limit. The left scrotum was enlarged, red, and tender on palpation, with positive fluctuation and skin induration. Due to swelling of the left scrotal pouch, the left testicle was unable to be assessed. Evaluation of the right scrotum and testis revealed normal findings. The transillumination test showed a negative result. The remainder of physical examination was within normal limit.

Blood test results were as follows: hemoglobin 12.3 g/dl, hematocrit 35.8%, leukocytes 19,910/ul, platelets 390,000/ul, total protein 8.9g/dL, albumin 2.89 g/dL, ureum 26.4 mg/dl, and creatinine 1.28mg/dl. Urinalysis revealed normal specific gravity (1.011) and pH (6.0), but found 46.5 red blood cells/hpf, 7 white blood cells/ hpf, proteinuria (1+), and bacteriuria (1+). Plain chest radiography findings reported increased bronchovascular markings and bilateral infiltrates on lower lobes of the lungs which were suggestive of bilateral pneumonia.

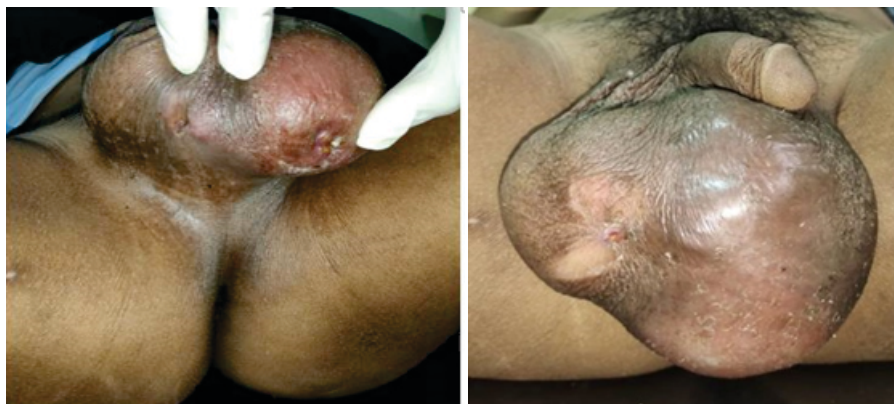

Figure 1. The left scrotum was enlarged, red, and tender on palpation, with fluctuation and skin induration.

Ultrasonography assessment of the urinary tract reported caliectasis of the left kidney without acoustic shadow, while the urinary bladder and right kidney appeared normal. An ultrasonography scan of the scrotum was also obtained. A hypoechoic lesion with internal echo was found on the left hemiscrotum, which suggested a presence of left scrotal abscess.

The scan demonstrated the left testicle as enlarged inhomogeneous parenchyma, measuring 2.5 x 2.9 x 3.5 centimeters with an estimated volume of 13,7 milliliters. These findings, accompanied by hypervascularization on colour doppler examination, were suggestive of left epididymoorchitis. Ultrasonography findings of the right testis and scrotum were within normal limits.

A hypoechoic lesion with internal echo was found on the left hemiscrotum, which suggested presence of left scrotal abscess. The left testicle was seen as enlarged inhomogeneous parenchyma, measuring 2.5 x 2.9 x 3.5 centimeters with an estimated volume of 13,7 milliliters. These findings, accompanied by hypervascularization on colour doppler examination, were suggestive of left epididymoorchitis. Ultrasonography findings of the right testis and scrotum were within normal limits.

Based on these findings, the patient was diagnosed with left scrotal abscess and hypoalbuminemia and subsequently treated with incisional drainage of abscess and necrotomy debridement under spinal anesthesia. He was also given intravenous ceftriaxone 1 g twice daily and a

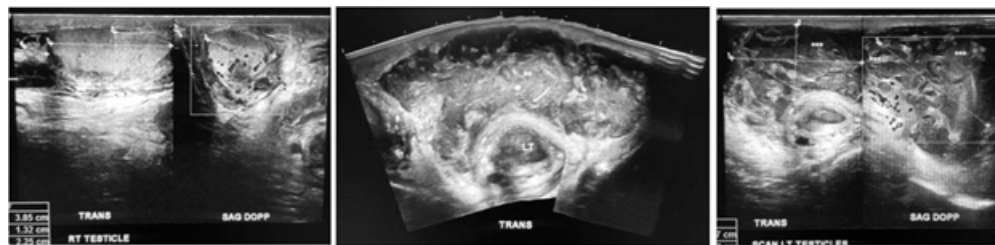


Figure 2. Ultrasonography of right testicle (left), scrotal sac (middle), and left testicle (right).

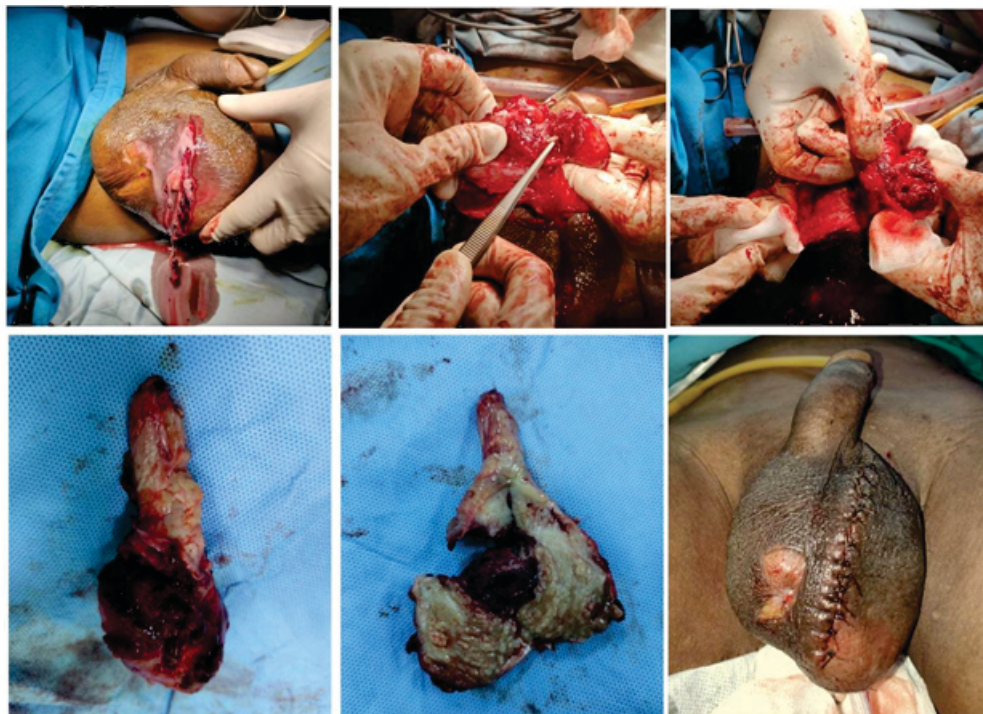

Figure 3. Incisional drainage of abscess and necrotomy debridement of the left scrotal sac was followed by left orchidectomy.

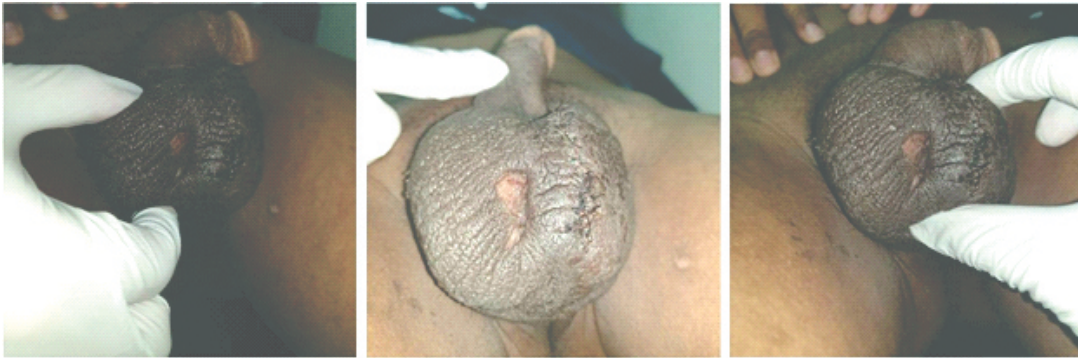


Figure 4. Follow-up physical examination one week after procedure revealed no signs of infection and marked improvement in testicular swelling with mild residual induration.

total of 1500 cc intravenous fluid support per 24 hours. Intraoperatively, the left hemiscrotum was incised longitudinally, which yielded approximately 50 milliliter of brownish yellow colored pus.

Around 5 milliliter of brownish yellow purulent discharge was found draining from the left testis. The left testicular tissue was found to be necrotic and considered nonvital, thus a left orchidectomy was decided. More pus accompanied by fibrotic tissue was observed when the testicle was split open.

A penrose drain was left in place, a sample of the purulent discharge was collected and sent for culture in order to identify antibiotic resistance and susceptibility, while the testicular and scrotal tissue was submitted for histopathology examination for further evaluation, particularly confirming presence of tuberculosis infection. The procedure was completed by a local dressing, a large gauze pressure pad and a scrotal support to prevent hematoma formation.

The post-operative period was successful without any complication. Penrose drain was removed the day after, and the patient was discharged 2 days after the procedure. He was put on oral prophylactic antibiotic for 7 days and scheduled for outpatient follow-up one week after procedure in the urology department. Follow-up physical examination revealed no signs of infection and marked improvement in testicular swelling with mild residual induration.

Histopathology of the specimen reported multiple epithelioid cell granulomas, caseous necrosis, and Langerhans type giant cells in the testis as well as epididymis and spermatic cord. Blood vessels showed congestion and there was infiltration

by lymphocytes and monocytes. Based on these findings, a diagnosis of tuberculosis orchitis and scrotal abscess was made. Patient was thereafter referred to the TB treatment centre and commenced on antituberculosis drug therapy on the day of follow-up.

DISCUSSION

Tuberculosis infection of scrotal contents is rare and occurs in approximately 7% of the patients with tuberculosis, although tuberculosis itself is a global epidemic with more than 2 billion of the world population infected.^{3,4,5,6} In patients with genital tuberculosis, pulmonary and renal tuberculosis can be documented in 50% and 80-85% respectively.⁴ It is often secondary to the pre-existing tuberculosis of the urinary tract, which may be confirmed by the culture of early morning urine specimens.³

The testicular abscess should be differentiated from other pathology causing acute scrotal conditions, such as acute epididymo-orchitis, Fournier's gangrene, acute filarial scrotum, testicular torsion, scrotal trauma, and incarcerated or strangulated scrotal hernia.⁷ History of inadequately treated acute epididymo-orchitis accompanied by complaints of unilateral testicular pain, swelling and scrotal erythema with a palpable, fluctuate, tender mass on examination should prompt consideration of testicular abscess.^{2,3} Bilateral presentation of testicular abscess is very unusual and few cases have been reported in the literature.¹

In this case, the patient did not appear sepsis which made a diagnosis of Fournier's gangrene became unlikely. Signs and symptoms of bowel obstruction was also not found in our patient,

therefore incarcerated or strangulated hernia was eliminated from the list of possible diagnosis. Acute filarial scrotum is usually accompanied by presence of hydrocele, characterized by positive transillumination test.⁷

Clinical symptoms and physical examination are often not enough for definite diagnosis due to pain and swelling that limit an accurate palpation of the scrotal contents.¹ Ultrasonography is very useful in evaluating an indurated scrotal mass and also in detecting the presence of a testicular abscess or ischemia.^{1,8} Characteristic findings of testicular abscess in ultrasonography is heterogeneous hypoechoic focus or mixed level echo region within an enlarged testis.^{2,9}

Culture of blood and pus are also recommended to help identify the causative organism of testicular abscess.⁴ Plain chest radiography and laboratory testing, such as routine blood examination and urinalysis, may be needed in detecting the source of infection, as it was documented that around 0-70% of patients with testicular tuberculosis have a history of tuberculosis infection in other organs (50% of patients were found to have positive radiologic findings of pulmonary tuberculosis).

In our patient, the source of infection was unknown, although the source may have been related to hematogenous spread from the respiratory tract and suspicion from thorax photo expertise. The lack of blood culture does not dismiss the possibility of an epididymo-orchitis as part of systemic infection with the testicular abscess as a local complication.^{1,10} Other confirmatory testing which is considered necessary before starting definitive treatment is histopathological examination, because tuberculous abscess may be misdiagnosed as tumor.^{3,10}

CONCLUSION

Treatment of testicular abscess is administration of appropriate antibiotics according to its causative organism accompanied by surgical

drainage. Early diagnosis and prompt treatment of testicular abscess is necessary, since chronic and severe cases, as happened in this patient, usually resulted in nonviable testicular tissue and necessitate orchidectomy. This may be due to cumulative ischemia of the testicles from multiple mechanisms: inflammatory infiltration causing compression of the spermatic cord, thrombosis secondary to venous congestion and/or bacterial exotoxins.

REFERENCES

1. Tena D, Leal F, Pozo B, Bisquert J. Bilateral testicular abscess due to *Streptococcus pneumoniae*. *International Journal of Infectious Diseases*. 2008 May 1; 12(3): 343-4.
2. Biswas S, Basu G. Causes & management of testicular abscess: findings of a study on eleven patients. *J. Dent. Med. Sci.(IOSR-JDMS)*. 2013; 9: 26-30.
3. Shahi K, Bhandari G, Rajput P, Singh A. Testicular tuberculosis masquerading as testicular tumor. *Indian journal of cancer*. 2009 Jul 1; 46(3): 250.
4. Michaelides M, Sotiriadis C, Konstantinou D, Pervana S, Tsitouridis I. Tuberculous orchitis US and MRI findings. Correlation with histopathological findings. *Hippokratia*. 2010 Oct; 14(4): 297.
5. Badmos KB. Tuberculous epididymo-orchitis mimicking a testicular tumour: a case report. *African health sciences*. 2012; 12(3): 395-297.
6. Furlow B. Tuberculosis: a review and update. *Radiologic technology*. 2010 Sep 1; 82(1): 33-52.
7. Murugan AU. A study on causes and management of acute scrotal conditions. *IAIM*. 2018; 5(7): 24-8.
8. Fehily SR, Trubiano JA, McLean C, Teoh BW, Grummet JP, Cherry CL, Vujovic O. Testicular loss following bacterial epididymo-orchitis: Case report and literature review. *Canadian Urological Association Journal*. 2015 Mar; 9(3-4): E148.
9. Mevorach RA, Lerner RM, Dvoretzky PM, Rabinowitz R. Testicular abscess: diagnosis by ultrasonography. *The Journal of urology*. 1986 Dec; 136(6): 1213-6.
10. Hane J, Duffey B, Kaiser R, Walker PF, Alpern JD. Case Report: Epididymo-Orchitis due to *Mycobacterium tuberculosis*. *The American journal of tropical medicine and hygiene*. 2019 Nov 6; 101(5): 1070-2.