

# A GIANT BLADDER STONE IN A YOUNG FISHERMAN FROM MOLUCCAS: A CASE REPORT

<sup>1</sup>Rakha Sulthan Salim, <sup>1</sup>Rabinda Fitriana Tuasikal, <sup>2</sup>Mo Tualeka.

<sup>1</sup> Dr. H. Ishak Umarella General Hospital, Maluku.

<sup>2</sup> Department of Surgery, Dr. H. Ishak Umarella General Hospital, Maluku.

## ABSTRACT

**Objective:** To present a rare case of a giant bladder stone. **Case(s) Presentation:** We report a 20-year-old fisherman, with excessive exposure to sunlight, poor fluid intake, and unhealthy lifestyle, who came to the hospital clinic with a 2-year-history of progressing dysuria, frequency, and hematuria. Investigations revealed a giant bladder stone without bladder outlet obstruction. Open cystolithotomy was performed and a giant stone with 13.2x8x8.3 cm in size was extracted without adhesion to the bladder wall. **Discussion:** A Giant bladder stone is a rare disease and fewer than 100 cases have been reported globally. Patients commonly are accompanied by multifactorial conditions and have a wide range of presentations. **Conclusion:** This case presents a giant bladder stone without bladder outlet obstruction in a young adult, it is considered that the stone rose due to other significant factors that followed the patient.

**Key words:** Urinary bladder calculi, young adult, hematuria.

## ABSTRAK

**Tujuan:** Menyajikan kasus langka batu kandung kemih raksasa. **Presentasi kasus:** Kami melaporkan kasus pada pria berusia 20 tahun yang bekerja sebagai nelayan. Pasien datang ke rumah sakit dengan keluhan berkemih berupa nyeri, frekuensi, dan hematuria. Pasien memiliki riwayat paparan sinar matahari berlebih, kurang minum air, dan gaya hidup yang tidak sehat. Pada pemeriksaan didapatkan Batu kandung kemih raksasa tanpa disertai obstruksi outlet kandung kemih. Dilakukan tindakan cystolithotomy terbuka, batu berukuran 13.2x8x8.3 cm dapat dikeluarkan tanpa adhesi pada dinding kandung kemih. **Diskusi:** Batu kandung kemih raksasa adalah kasus yang jarang ditemukan, kurang dari 100 kasus telah dilaporkan secara global. Pasien biasanya memiliki berbagai faktor resiko dan datang dengan gambaran klinis yang bervariasi. **Simpulan:** Kasus ini menyajikan batu buli raksasa tanpa obstruksi outlet kandung kemih pada pasien dewasa muda, kami mempertimbangkan bahwa batu dipengaruhi faktor-faktor lain yang juga signifikan pada pasien.

**Kata kunci:** Batu kandung kemih, dewasa muda, hematuria.

Correspondence: Rakha Sulthan Salim, c/o: Dr. H. Ishak Umarella General Hospital, Jl. Pahlawan No.36, Tulehu, Maluku 97582, Indonesia. Mobile Phone: +6285397488416. Email: rakasulthan@gmail.com.

## INTRODUCTION

Urinary stone is one of the most common urinary tract diseases in Asia.<sup>1-2</sup> Bladder stone, contributing to 5% of all urolithiasis cases, is the most common stone in the lower urinary tract.<sup>3-4</sup> Giant stones are those weighted more than 100 grams. Less than 100 cases have been reported<sup>3</sup>, and fewer cases are found in the modern era.<sup>2,3</sup>

Bladder stone has been a problem since ancient times; it has been the cause of suffering and demise. Despite once affecting worldwide, bladder stone cases have been progressively disappearing from developed countries, but the situation is

different in developing countries where the disease is still a burden.<sup>5</sup>

This is a case report of a young fisherman in an archipelago area of Moluccas, part of a rural area in Indonesia. Associated with unbalanced diets, high sunlight exposure, poor fluid intake, and unhealthy lifestyle, he presented with a giant bladder stone.

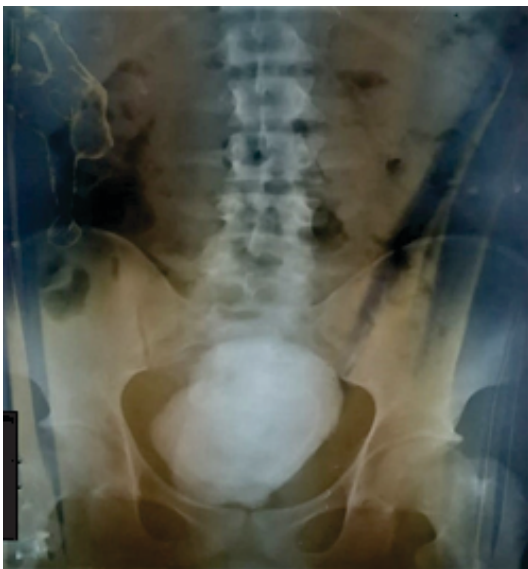## CASE(S) PRESENTATION

A 20-year-old male came to the hospital clinic with a 2-year-history of urinary progressing dysuria, frequency, and hematuria. There was also a complaint of constipation which was thought to be

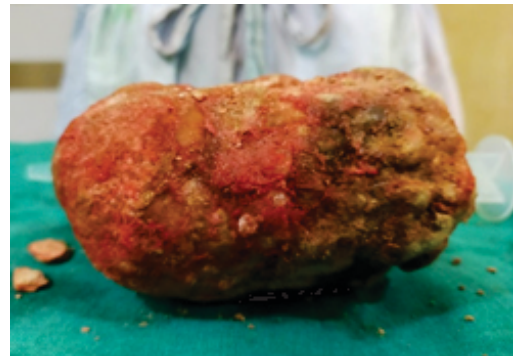
related. Three years before, the patient had a history of passing stones, consulted and received an ultrasound scan from a physician, a bladder stone, approximately 60mm in size, was found but the patient chose not to seek further treatment. The patient was a fisherman with high exposure to sunlight and dehydration related to long working hours. He had a history of drinking 170 g of alcohol and smoking 20 cigarettes every day for the last 7 years. In the past year, the patient had received several antibiotic treatments due to recurrent lower urinary tract infections.

During physical examination, suprapubic solid mass was palpable. No prostate enlargement was found. A kidney-ureter-bladder x-ray showed a giant-opaque-intravesical mass with 12cm x 8.5cm in size (Fig. 1). Routine urine examination showed no sign of infection.

Intravenous antibiotics administered preoperatively. Open cystolithotomy was performed under general anesthesia. The bladder stone, measured 13.2cm x 8cm x 8.3cm in size (Fig. 2) and weighed approximately 940 grams, was extracted without adhesion to the bladder wall. Stone analysis was not performed due to several circumstances. An indwelling urethral catheter was placed for 5 days, showed normal urine flow rate, and perivesical drainage was placed for 2 days. The patient was discharged after 7 days and followed up after 6 months, showed no remaining urinary and defecatory symptoms.



**Figure 1.** Kidney-ureter-bladder film shows a large opaque mass inside the bladder.



**Figure 2.** Bladder stone, 13.2x8x8.3 cm in size, extracted with open cystolithotomy.

## DISCUSSION

Bladder stone is considered a rare disease,<sup>6</sup> which makes a giant bladder stone an even rarer case. Associated with many different factors, the prevalence of urinary stones varies. In developed countries, urinary tract stones ranged between 4-20%,<sup>3</sup> numbers are different in developing countries, in Southeast Asia, it ranged between 5%-19.1%.<sup>1</sup>

The majority of Indonesians, especially those with low socioeconomic status, are working in rough conditions.<sup>2</sup> In this case, the patient worked as a fisherman and was associated with high exposure to sunlight and poor fluid intake. The incidence of urolithiasis is higher in the population with more laborious work, because it is more likely to have an unhealthy lifestyle, irregular diet, and less fluid intake thus leading to dehydration. Furthermore, people with outdoor working activities and high temperatures are twice as likely to suffer from urolithiasis. Hot temperature accelerates evaporation from skin, accompanied by low fluid intake, which can lead to dehydration and concentrated urine. Excessive exposure to sunlight can lead to higher production of vitamin D, which further drives calcium absorption in the gut.<sup>1</sup>

Males have higher calculi incidence than females. Apart from anatomical and hormonal differences, it might be caused by dietary habits in which men are more likely to consume unhealthy and irregular diets.<sup>1</sup>

Bladder stone is classified into migrating calculi, primary, and secondary.<sup>4,7</sup> Migrating stone developed in the upper urinary tract and migrated through ureter into the bladder. Secondary stone are associated with underlying conditions such as

urinary stasis, inadequate bladder contraction, chronic bacteriuria, foreign bodies, bladder diverticula, and urethral passage problems.<sup>6-7</sup> Bladder outlet obstruction is one of the most frequent cause, it might be present in >75% of bladder stone cases. Primary stones develop in the absence of underlying conditions. It is more common in children, the pathogenesis is still unclear, but most likely involved a combination of metabolic factors that affect the volume, acidity, and compositions of urine.<sup>7</sup>

The young adult stone population has been neglected in most population studies, and little is known about its clinical and metabolic characteristics.<sup>8-9</sup> Studies showed that metabolic abnormalities were found in 91% of young adult stone population, and hypercalciuria<sup>8</sup> or hypocitraturia<sup>9</sup> are the most frequent abnormalities. Around 40-60% of the populations with calcium stones are found to have hypercalciuria. Hypercalciuria can be idiopathic or secondary to conditions such as primary hyperparathyroidism, renal tubular acidosis, or malignancy. Consumption of alcohol, caffeine, high sodium, and high protein was also shown to be associated with increased urinary calcium.<sup>10</sup>

The composition of urinary stones may vary, influenced by diet, lifestyle, associated comorbidities, and also geographies with different cultures.<sup>1,11-12</sup> In Asia, calcium oxalate is the most common composition (75-90%).<sup>1</sup> Other composition are uric acid, calcium phosphate, ammonium urate, cysteine, and struvite.<sup>11</sup> In developing countries, especially in rural areas, calcium phosphate and calcium oxalate are the composition of the main stone due to high dietary oxalate from green vegetable diet, high urinary ammonia due to low dietary phosphorus, and low citrate intake.<sup>11</sup>

Common signs of bladder stone are intermittent voiding hematuria, storage symptoms, and painful voiding specifically near the end of micturition.<sup>6</sup> Bladder stone patients have a wide range of presentations, from completely asymptomatic to fatal hemodynamic instability. While some asymptomatic stones were reported to be found accidentally,<sup>9</sup> a report was made on a septic shock following urosepsis in a giant bladder stone patient.<sup>3</sup>

Bladder stones are generally diagnosed in older males that are affected by urinary stasis.<sup>6</sup> Bladder stone without urinary outlet obstruction is an uncommon presentation.<sup>3</sup>

Several modalities are available to provide diagnosing of bladder stones. Ultrasonography usually is the first modality used, and cystoscopy is the most accurate. An x-ray can show the presence of stone, but only when it contains calcium. A CT scan has high accuracy in detecting urinary stones, however, it has a higher cost.<sup>6</sup> In a study of 42 bladder stone patients in rural areas of India, ultrasonography detected the stone in all cases, whereas x-ray could detect 93% of cases.<sup>4</sup> In this case, both ultrasonography and x-ray were enough to confirm the presence of a bladder stone.

In the last few centuries, management of bladder stone has been highly developed, with newer technologies providing a less invasive approach.<sup>3</sup> Despite the open approach being continuously replaced, it is still considered the realistic approach in larger stone, atypical stone presentation, or when advanced options are not available.<sup>3,6</sup>

The recurrence rate of urinary stones is estimated around 50%, affected by the types of stone, underlying causes, and post-treatment prevention. Correction of dietary imbalance and insufficient water intake considered as the main factors that should prevent stone recurrences.<sup>13</sup> When treated properly, the prognosis of bladder stones are good, whilst untreated bladder stones can lead to damaged urinary tract, infection, and stones recurrence.<sup>11</sup>

## CONCLUSION

Giant Bladder stone is a rare disease. Although it has significantly decreased in developed countries, it is still a problem in the developing world. Bladder stone provides a significant burden, especially for those with low income, patients might delay treatment considering economic factors. With a variety of available developed techniques, open cystolithotomy is still considered a realistic approach in giant bladder stone cases.

Stone prevalence is affected by multifactorial conditions. Dietary imbalance, unhealthy lifestyle, hot climate, dehydration, and excessive sunlight exposure are some conditions that follow the patient. Giant bladder stone without bladder outlet obstruction is uncommon. In this case, the stone might arise due to other significant factors.

## REFERENCES

1. Liu Y, Chen Y, Liao B, et al. Epidemiology of urolithiasis in Asia. *Asian J Urol.* 2018; 5(4): 205-214.

2. Pattilha AM, Hadi AF, Rokhimah S, et al. Giant bladder uric acid stone with a history of prolonged sun exposure and high protein diet in North Moluccas: Case series. *Int J Surg Case Rep.* 2020; 73: 328-331.
3. Vidhyarthi AK, Hameed T, Lal R, et al. Giant Bladder Calculus in an Adult- A Persistent Problem in the Developing World: A Case Report. *Clin Pract Cases Emerg Med.* 2020; 4(4): 544-547.
4. Malladad N, Manjunath DA, Anil R, et al. Clinical study and management of vesical calculus. 2018; 5(4): 1281-1285.
5. Halstead SB. Epidemiology of bladder stone of children: precipitating events. *Urolithiasis.* 2016; 44(2): 101-108.
6. Cicione A, C DEN, Manno S, et al. Bladder stone management: an update. *Minerva Urol Nefrol.* 2018; 70(1): 53-65.
7. Philippou P, Moraitis K, Masood J, et al. The management of bladder lithiasis in the modern era of endourology. 2012; 79(5): 980-986.
8. Spivacow FR, Negri AL, Del Valle EE, et al. Clinical and metabolic risk factor evaluation in young adults with kidney stones. 2010; 42(2): 471-475.
9. Kang HW, Seo SP, Kim WT, et al. Metabolic characteristics and risks associated with stone recurrence in Korean young adult stone patients. 2017; 31(8): 806-811.
10. Escribano J, Balaguer A, i Figuls MR, et al. Dietary interventions for preventing complications in idiopathic hypercalciuria. 2014: 2.
11. Leslie SW, Sajjad H, Murphy PB. Bladder Stones. In: *StatPearls.* Treasure Island (FL). 2021.
12. Raheem OA, Khandwala YS, Sur RL, et al. Burden of Urolithiasis: Trends in Prevalence, Treatments, and Costs. *Eur Urol Focus.* 2017; 3(1): 18-26.
13. Daudon M, Jungers P, Bazin D, et al. Recurrence rates of urinary calculi according to stone composition and morphology. *Urolithiasis.* 2018; 46(5): 459-470.