

GIANT NON-FUNCTIONING ADRENOCORTICAL CARCINOMA

¹Ivandy Fam, ¹Decky Kasman, ¹Dilino Ryan Guntoro, ¹Isdiyanto Septiadi.

¹Departement of Urology, Navy Hospital Dr. Mintohardjo, Jakarta.

ABSTRACT

Objective: This study aims to report a case of a 51 year old male who was referred to our Department of Urology and was diagnosed with a nonfunctioning giant ACC. **Case(s) Presentation:** The case report describes a 51-year-old Indonesian man who presented to our department with complaints of persistent upper left abdomen discomfort, previously misdiagnosed as dyspepsia. He was diagnosed as having non-functioning adrenocortical carcinoma and underwent open adrenalectomy. **Discussion:** Although the patient is 51 years old and the tumor has grown to a significant size, no lymph node involvement or metastases was found and resection margins were found to be negative. In our patient, functional adrenal work-up results were normal. This has led us to suspect a non-functioning adrenal tumor. Metastatic work-up with CT cranial, chest, and bone survey were performed, with negative result. The biopsy result after resection confirmed the diagnosis of ACC. **Conclusion:** ACC is a rare aggressive tumor, malignant with poor prognosis. In our case, the non-secreting mass was diagnosed late by manifestation of mass effect symptoms in the upper left quadrant of the abdomen and was previously misdiagnosed as symptoms of dyspepsia. The functional work-up of adrenal masses helped in the determination of its non-functional status. Early diagnosis of ACC and early surgical excision helps in improving the overall survival rate of the patient.

Keywords: Non-functioning, adrenocortical carcinoma (ACC), adrenalectomy, case report.

ABSTRAK

Tujuan: Penelitian ini bertujuan untuk melaporkan kasus seorang pria berusia 51 tahun yang dirujuk ke Departemen Urologi kami dan didiagnosis dengan ACC yang tidak berfungsi. **Presentasi Kasus:** Laporan kasus memaparkan seorang pria di Indonesia berusia 51 tahun yang datang ke departemen kami dengan keluhan ketidaknyamanan perut kiri atas yang persisten, yang sebelumnya salah didiagnosis sebagai dispepsia. Dia didiagnosis memiliki adrenokortikal karsinoma yang non-sekretorik dan menjalani open adrenalectomi. **Diskusi:** Meskipun pasien berusia 51 tahun dan tumor telah tumbuh menjadi ukuran yang tidak jelas, tidak ada keterlibatan kelenjar getah bening atau metastasis yang ditemukan dan margin reseksi ditemukan negatif. Pada pasien kami, hasil kerja adrenal fungsional normal. Hal ini membuat kami mencurigai adanya tumor adrenal yang tidak berfungsi. Pemeriksaan metastatik dengan CT kranial, dada, dan survei tulang dilakukan, dengan hasil negatif. Hasil biopsi setelah reseksi telah mengkonfirmasi diagnosis ACC. **Simpulan:** ACC adalah tumor agresif yang jarang, ganas dengan prognosis buruk. Dalam kasus kami, massa non-sekretori didiagnosis terlambat dengan manifestasi gejala efek massa di kuadran kiri atas perut, dan sebelumnya salah didiagnosis sebagai gejala dispepsia. Pemeriksaan fungsional massa adrenal membantu dalam penentuan status non-fungsionalnya. Diagnosis dini ACC dan eksisi bedah dini membantu meningkatkan tingkat harapan hidup pasien secara keseluruhan.

Kata kunci: Non-fungsional, adrenokortikal karsinoma (ACC), adrenalectomi, laporan kasus.

Correspondence: Ivandy Fam; c/o: Department of Urology, Navy Hospital Dr. Mintohardjo. Jl. Bendungan Hilir No. 17, Tanah Abang, DKI Jakarta 10210, Indonesia. Phone: (021) 5703081. Email: ivandyfam@gmail.com.

INTRODUCTION

Adrenocortical carcinoma (ACC) is a rare and aggressive malignant tumor. There are an estimated 1-2 cases per million per year. ACC is found to be more common in female (55-60%) as compared to the male population.¹ Epidemiological

studies have shown that ACC has a bimodal age distribution of 5 to 20 years and 40 to 50 years.²

Approximately 60% of all the adrenal masses are hyperfunctioning (hormone secreting) while the rest 40% are non-functioning (non-hormone secreting).³ The symptoms were found to be variable, with most (40-60%) cases present with

symptoms of steroid hormone excess, most commonly being hypercortisolemia, 30% of the cases present with symptoms related to abdominal mass effects, as in our case, and around 15-20% of the cases are incidentally diagnosed.⁴ Imaging plays a crucial role in the identification of ACC, in the determination of possible malignancy, in staging evaluation, and post-operative follow-up.⁵ Histological and immunohistochemical tests can be used to confirm the diagnosis and help in the determination of prognosis of an adrenocortical tumor, and guide the appropriate treatment of choice.⁶

We present a case of a 51 year old male who was referred to our Department of Urology and was diagnosed with a nonfunctioning giant ACC. The patient underwent an open complete resection.

CASE(S) PRESENTATION

A 51-year-old male presented to the urologic department after being referred by an internist. He complained of a persistent progressive left upper abdomen discomfort that was previously diagnosed as chronic gastritis over the past 8 months and was treated with PPIs without substantial relieve of the symptom. He also complained of difficulty in achieving satisfactory inspiration while breathing in certain positions. He was not on any medication, and he was not an active tobacco smoker. His family history was unremarkable for any illness or causative factor. At the time of admission, his blood pressure was 140/90, his pulses were 90 beats/minute, and he was afebrile with a temperature of 36.7°C. Upon physical examination, a palpable non-tender mass was found on the left upper quadrant of the abdomen. Other physical examination findings were normal.

A computed tomography (CT) scan with contrast showed a large mass measuring

approximately 11.5cm in its greatest dimension (11.48x9.84x10.53cm) that originated from his left adrenal gland, compressing his pancreas, left kidney, and left renal artery (Fig. 1).

Laboratory tests revealed a rise in C-reactive protein (CRP) levels. Renal, hepatic, and functional adrenal work-up was ordered. The functional adrenal work-up included serum electrolytes (sodium, potassium, and magnesium) and cortisol levels. The results were within normal limit. The laboratory results are shown in Table 1. A non-functional left adrenocortical carcinoma (ACC) was suspected.

Further work-up for metastases were performed, which included CT scans of cranial, chest, and bone survey. The results revealed no metastases.

Table 1. Laboratory Finding.

| Test | Result | Reference range |
|--------------------------------|--------|-----------------|
| Hemoglobin (g/dL) | 12.2 | 13.2-17.3 |
| Hematocrit (%) | 37 | 40-52 |
| WBC (10 ³ /uL) | 9.5 | 3.8-10.6 |
| Platelet (10 ³ /uL) | 505 | 150-440 |
| Glucose (mg/dL) | 90 | 70-180 |
| Ureum (mg/dL) | 25 | 5-35 |
| Creatinine (mg/dL) | 1.0 | 0.6-1.1 |
| SGOT (U/L) | 49 | 8-35 |
| SGPT (U/L) | 40 | 4-35 |
| Sodium (mmol/L) | 139 | 135-147 |
| Chloride (mmol/L) | 101 | 100-110 |
| Potassium (mmol/L) | 4.4 | 3.5-5.5 |
| Magnesium (%) | 2.2 | 1.6-2.5 |
| Morning Serum Cortisol (ug/dL) | 12.3 | 3.7-19.4 |
| CRP (mg/dL) | 5.5 | <0.5 |

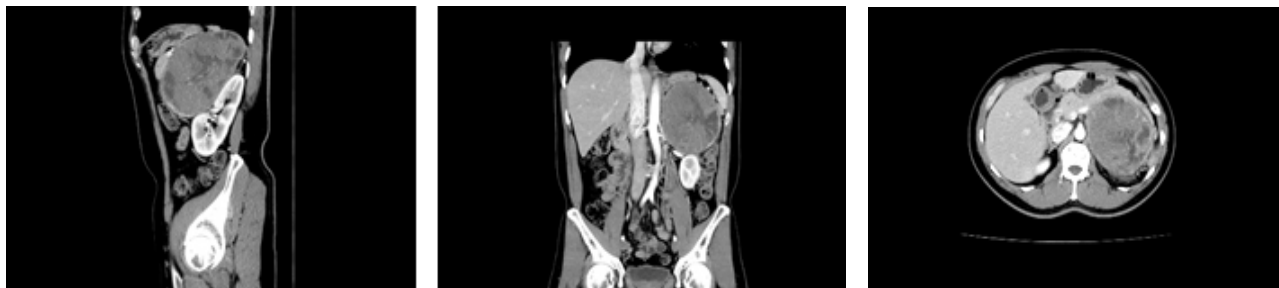

Figure 1. CT Scan appearance of giant adrenal tumor.

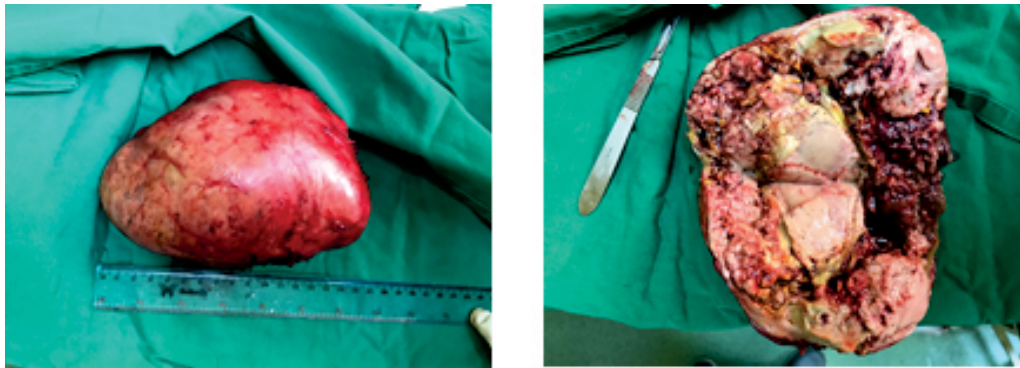


Figure 2. Intraoperative finding of the giant adrenal tumor, with cross-cut section showing foci of hemorrhage and necrosis.

The patient was then scheduled for elective open adrenalectomy, and the tumor was removed completely with its capsule, and since there was no infiltration, no excision of adherent organs were needed. The tumor turned out to be much larger in dimension than that of the CT scan, being 17 cm in its greatest dimension (Fig. 2). Postoperative pathology results confirmed the diagnosis of ACC (Fig. 3).

DISCUSSION

Majority of patients with ACC, approximately 60%, present with symptoms due to excessive hormonal secretion.³ In our case, however, the ACC was not functional, and the patient presented with symptoms of mass effect. Hormone secretion is not a differentiating factor between benign and malignant adrenocortical tumors. It is due to the silent nature of the nonfunctioning ACC tumor that results in poorer outcome, because majority of the patients present with already advanced local or metastatic disease.⁷ Our patient presented with symptoms of mass effect and complained of fullness and discomfort in right upper abdomen region, which was mistakenly diagnosed previously as dyspepsia. When finally diagnosed with adrenal tumor, it had grown to a size of 17cm in its greatest dimension. Positive prognostic factors that could improve the overall survival rate are early stage disease without any lymph node involvement or metastasis, an age of younger than 40 years, and also negative resection margins (Ro).⁷ In our case, although the patient is 51 years old and the tumor has grown to a significant size, no lymph node involvement or metastases was found and resection margins were found to be negative.

It is important to determine whether the adrenocortical tumor is functional or non-functional,

via functional adrenal work-up. It is also important to rule out whether it is benign or malignant, or whether it is locally advanced or it has metastasized.¹ Radiographic studies in the form of CT scan or Magnetic resonance imaging (MRI) can help measure the size of the mass and rule out metastases. It has been noted that large tumors with measurement greater than 4 cm should raise a high suspicion of malignancy, as in our case, hence the indication for adrenalectomy. Studies have shown that fluorodeoxyglucose position emission tomography (FDG-PET) combined with CT is superior in diagnosing ACC compared to CT alone.⁸ However, FDG-PET/CT is still considered complementary study, and has yet been recommended for routine ACC work-up.^{3,8} In our patient, functional adrenal work-up results were normal. This has led us to suspect a non-functioning adrenal tumor. Metastatic work-up with CT cranial, chest, and bone survey were performed, with negative result. The biopsy result after resection has confirmed the diagnosis of ACC.

It is known that despite the poor prognosis of ACC, chemotherapy has been found to have little role in the treatment of ACC, and the best outcome is achieved by complete Ro surgical resection.⁹ However, newer studies have suggested a role for adjuvant chemotherapy in prolonging recurrence-free survival and overall survival rate.¹⁰ Chemoradiation could be considered in patients with stage I-III ACC to increase disease-free survival.³ In cases of recurrence, however, surgery should still be considered as the first-line option. For surgical treatment, open approach is preferred if the patient is symptomatic, with mass greater than 6 cm, or if malignancy is suspected.¹¹ Laparoscopic surgery is indicated for small tumors as long as there is no infiltration to adjacent organs or capsular

disruption.¹⁰ In our patient, the open approach was chosen, the patient was positioned in a supine position, and the adrenal tumor was visualized by subcostal incision and subsequent incision of the abdominal musculature. The adrenal tumor was resected in toto, and the patient was not considered for adjuvant chemotherapy.

In cases of stage IV ACC or recurrent metastatic disease, mitotane should be considered.¹² Mitotane's toxicity and its ability to inhibit adrenocortical steroid biosynthesis and induce hepatic clearance of cortisol prove valuable in controlling the disease.¹² Alternatively, en bloc incision of involved organs or metastectomy could be considered to improve overall survival.¹⁰ Postoperative surveillance for recurrence should be performed every 3 months for the first 2 years and then every 6 months for 5 years.

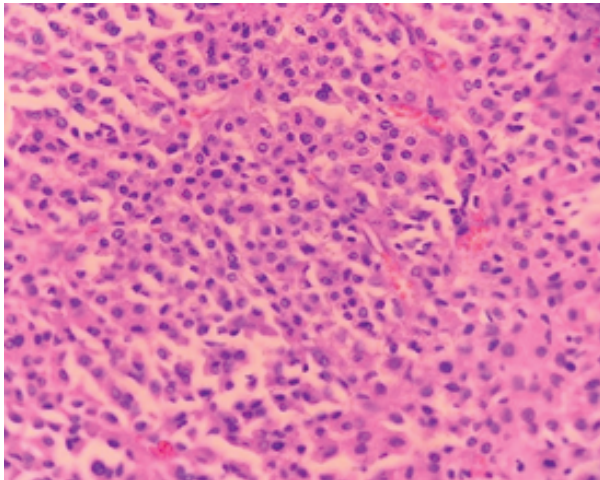


Figure 3. Part of the tumor, where the neoplastic cells show nuclear pleomorphism; Thin capillaries are evident between neoplastic cells. Hematoxylin and eosin $\times 40$.

CONCLUSION

ACC is a rare aggressive tumor, malignant with poor prognosis. In our case, the non-secretory mass was diagnosed late by manifestation of mass effect symptoms in the upper left quadrant of the abdomen and was previously misdiagnosed as symptoms of dyspepsia. The functional work up of adrenal masses helped in the determination of its non-functional status.

Radiological findings and histopathological examination was crucial in the diagnosis of the disease. There was no evidence of metastasis, and

complete excision of the tumor was the treatment of choice. The tumor was excised in-toto and the surgical margin was negative. Early diagnosis of ACC and early surgical excision helps in improving the overall survival rate of the patient.

REFERENCES

1. Kostianen I, Hakaste L, Kejo P, Parviainen H, Laine T, Löyttyniemi E, et al. Adrenocortical carcinoma: presentation and outcome of a contemporary patient series. *Endocrine* [Internet]. Springer US; 2019; 65(1): 166-74.
2. Bacalbasa N, Terzea D, Jianu V, Marcu M, Stoica C, Balescu I. Multiple visceral resection for giant non-secretory adrenocortical carcinoma in an elderly patient: A case report. *Anticancer Res.* 2015; 35(4): 2169-74.
3. George C, Ioannis P, Dimitra-Rafailia B, Dimitrios G, Alexandros K, Konstantinos I, et al. Giant nonfunctioning adrenal tumors: Two case reports and review of the literature. *J Med Case Rep. Journal of Medical Case Reports*; 2018; 12(1): 4-9.
4. Else T, Kim AC, Sabolch A, Raymond VM, Kandathil A, Caoili EM, et al. Adrenocortical carcinoma. *Endocr Rev.* 2014; 35(2): 282-326.
5. Bharwani N, Rockall AG, Sahdev A, Gueorguiev M, Drake W, Grossman AB, et al. Adrenocortical carcinoma: The range of appearances on CT and MRI. *Am J Roentgenol.* 2011; 196(6): 706-14.
6. Erickson LA. Challenges in surgical pathology of adrenocortical tumours. *Histopathology.* 2018; 72(1): 82-96.
7. Almarzouq A, Asfar S, Hussain S, Al-Hunayan A, Aldousari S. Giant nonfunctioning adrenocortical carcinoma: A case report and review of the literature. *BMC Res Notes.* 2014; 7(1).
8. Deandreis D, Lebouilleux S, Caramella C, Schlumberger M, Baudin E. FDG PET in the management of patients with adrenal masses and Adrenocortical carcinoma. *Horm Cancer.* 2011; 2(6): 54-62.
9. Ayala-Ramirez M, Jasim S, Feng L, Ejaz S, Deniz F, Busaidy N, et al. Adrenocortical carcinoma: Clinical outcomes and prognosis of 330 patients at a tertiary care Center. *Eur J Endocrinol.* 2013; 169(6): 891-9.
10. Benassai G, Desiato V, Benassai G, Bianco T, Sivero L, Compagna R, et al. Adrenocortical carcinoma: What the surgeon needs to know. Case report and literature review. *Int J Surg* [Internet]. Elsevier Ltd; 2014; 12: S22-8.
11. Polavarapu. Adrenocortical Carcinoma: Complete Surgical Resection After 18 Years. *World J Oncol.* 2011; 2(6): 307-10.
12. De Francia S, Ardito A, Daffara F, Zaggia B, Germano A, Berruti A, et al. Mitotane treatment for adrenocortical carcinoma: an overview. *Minerva Endocrinol. Italy*; 2012 Mar; 37(1): 9-23.