

# AN UNDIAGNOSED FOURNIER'S GANGRENE IN ADVANCED UROGENITAL CANCER WITH INCARCERATED INGUINAL HERNIA

<sup>1</sup>Hylman Mahendra, <sup>2</sup>Syamsuhadi Alamsyah.

<sup>1</sup> Department of Emergency Cibinong General Hospital, Bogor.

<sup>2</sup> Department of Urology Cibinong General Hospital, Bogor.

## ABSTRACT

**Objective:** This study aims to report an undiagnosed Fournier's gangrene. **Case(s) Presentation:** A 62-year-old male with advanced urogenital cancer and an incarcerated inguinal hernia. Sudden-onset scrotal pain was initially diagnosed as hydrocele with an incarcerated hernia. Radiological examinations not revealing typical Fournier's gangrene features. Despite the absence of classical symptoms, further investigation uncovered a complex medical history involving urogenital issues, failed catheterization, and urethrotomy. The patient presented with malnutrition, weight loss, and signs of systemic distress. **Discussion:** Pus and necrotic tissue were debrided, with cultures indicating *E. Coli* growth. Biopsies suggested carcinoma, requiring further evaluation at a tertiary facility. Despite complications, the patient showed an excellent prognosis after a 14-day hospital stay. **Conclusion:** This case underscores the atypical presentation of Fournier's gangrene, emphasizing the need for comprehensive assessment in patients with scrotal pain. The association with advanced urogenital cancer adds complexity to diagnosis and management, highlighting the importance of a multidisciplinary approach.

**Keywords:** Fournier's gangrene, urogenital cancer, incarcerated inguinal hernia.

## ABSTRAK

**Tujuan:** Penelitian ini bertujuan untuk melaporkan Gangren Fournier yang tidak terdiagnosis. **Presentasi Kasus:** Seorang pria berusia 62 tahun dengan kanker urogenital lanjut dan hernia inguinal inkarserata. Nyeri secara mendadak pada skrotum pada awal terdiagnosa sebagai hidrokel dan hernia inguinal inkarserata, dengan pemeriksaan radiologi yang tidak memberikan gambaran khas pada Gangren Fournier. Meskipun tidak ada gejala klasik, penyelidikan lebih lanjut mengungkap riwayat kompleks yang melibatkan masalah urogenital, diantaranya gagal kateterisasi, dan riwayat uretrotomi. Pasien datang dengan status malnutrisi, penurunan berat badan, dan tanda-tanda distress sistemik. **Diskusi:** Pus dan jaringan nekrotik dibersihkan, hasil kultur menunjukkan pertumbuhan *E. Coli*. Biopsi menunjukkan karsinoma yang memerlukan evaluasi lebih lanjut di fasilitas tersier. Meskipun ada komplikasi, pasien menunjukkan prognosis yang sangat baik setelah perawatan selama 14 hari. **Simpulan:** Kasus ini menekankan presentasi tidak biasa dari Gangren Fournier, menyoroti perlunya penilaian komprehensif pada pasien dengan nyeri skrotum. Asosiasi dengan kanker urogenital lanjut menambah kompleksitas pada diagnosis dan penanganan menunjukkan pentingnya pendekatan multidisiplin.

**Kata Kunci:** Gangren Fournier, kanker urogenital, hernia inguinal inkarserata.

Correspondence: Hylman Mahendra; c/o: Department of Emergency, Cibinong General Hospital. Jl. KSR Dadi Kusmayadi No.27, Bogor 16914, Indonesia. Phone: +6287700243419. Email: hylmanm@gmail.com.

## INTRODUCTION

Fournier's gangrene, also known as necrotizing fasciitis, is a rare and potentially life-threatening genital skin disease that results from infections in the urogenital tract, anorectal region, and genital area. This condition typically occurs in immunocompromised individuals, including those with malnutrition, diabetes, malignancy, substance

abuse (drugs or alcohol), HIV, obesity, or a combination of these factors. The management of Fournier's gangrene involves surgical intervention and antibiotic therapy.<sup>1-2</sup>

This case is particularly interesting because Fournier's gangrene typically manifests with gradual scrotal pain. However, in this patient, the pain was sudden, and the initial diagnoses was hydrocele and incarcerated left inguinal hernia, and on radiological

examinations, including CT urogram and ultrasound did not exhibit the typical features of Fournier's gangrene.

### CASE(S) PRESENTATION

A 62-year-old male presented to the ER with a chief complaint of sudden pain in his scrotum three hours before admission. His scrotum was enlarged, and the patient also reported nausea, difficulty urinating, and diaphoresis. There was no complaint of fever, and no prior history of scrotal pain was noted. Six months earlier, he had complained about a mass that appeared intermittently in his left inguinal region. The patient also had a history of low dietary intake, resulting in a weight loss of about 20 kilograms over the past three months. Around that time, he began experiencing difficulty urinating and complained of edema in his bilateral lower limbs. He sought emergent assistance for catheterization, which unfortunately was unsuccessful. About two months before admission, he underwent internal urethrotomy because his urethrography revealed stricture and diverticula, which may be linked to his failed catheterization in the emergency room.

Vital signs assessment showed a blood pressure of 110/70 mm Hg, a heart rate of 100 beats per minute, a respiratory rate of 25 breaths per minute, and a temperature of 36°C. Anthropometric measurements indicated a body weight of 45 kg, a height of 170 cm, and a BMI of 15.57 kg/m<sup>2</sup>. With a BMI below 18 kg/m<sup>2</sup>, this suggests that the patient was in a malnourished condition.

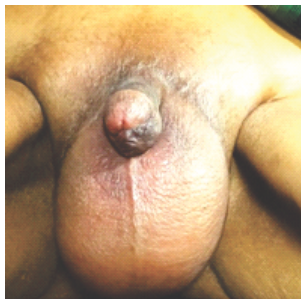During the physical examination, a non-reducible mass was identified in the left inguinal to scrotal region. External genital examination revealed an enlarged, erythematous scrotum with a negative transillumination test. The scrotum felt tender and warm. All other findings from the general physical examination were within normal limits.

Complete blood count revealed that haemoglobin 8.4 gr/dL, leukocytes 27.150/μL, hematocrit 23.7%. The blood chemistry panel showed that random blood sugar 84 mg/dL, sodium 136 mEq/L, potassium 6.7 mEq/L, chloride 110mEq/L, ureum and creatinine levels are 248 mg/dL, 7.4 mg/dL, respectively. Then the patient was taken care for the abnormal blood work with antibiotics, hemodialysis, and other supportive management to get electrolyte and ureum-creatinine levels to be optimal so we could perform the surgery.

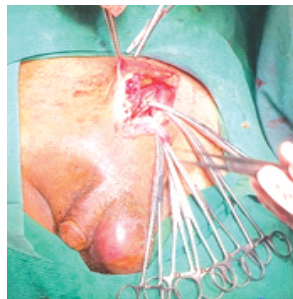
An emergency urologist consultation was sought, leading to the urologist ordering scrotal ultrasonography and a CT urogram. Radiological expertise revealed the presence of a mass in the bladder, a left inguinal hernia, and a hydrocele. However, a diagnosis of Fournier's gangrene was not explicitly mentioned.

Antibiotics, blood transfusions, hemodialysis, and other supportive treatments are administered to the patient to achieve optimal condition for surgery. The surgery involved collaboration between a urologist and a general surgeon. Initially, the urologist performed cystoscopy, revealing multiple masses in the prostate and bladder. Subsequently, a biopsy was conducted, followed by herniorrhaphy. Pus was discovered from the incision opening to the inguinal canal, extending from the subcutaneous layer to the muscle layer. The pus and surrounding tissue were debrided.

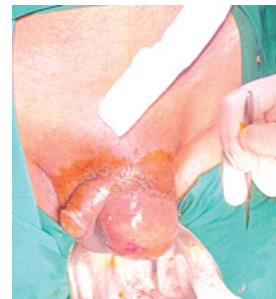After the herniorrhaphy, the scrotum remained swollen, prompting an incision to drain pus. The incision was extended to explore the surroundings and debride necrotic tissue. The infection was limited in the tunica dartos to scarpa's fascia, with no extension to the contralateral scrotum, perineal area or deeper abdominal fascia. The spermatic fascia in the left testis remained intact. The patient was discharged approximately 14 days after presentation with an excellent prognosis.



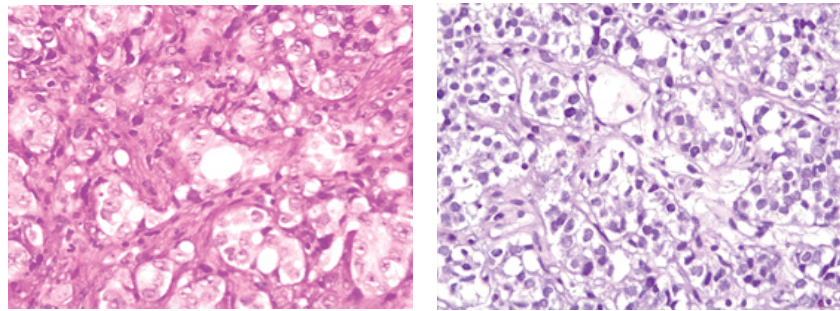
**Figure 1.** Image of swelling and erythematous of the scrotum



**Figure 2.** Intraoperative image debridement of the abdominal wall and herniorrhaphy afterwards



**Figure 3.** Intraoperative image of initial incision of the scrotum



**Figure 4.** Histopathology of biopsied prostate and bladder masses.

Cultures of the wound and surgical specimens revealed the growth of *E. coli* [single microorganism], and biopsies indicated proliferative epithelial cells suggestive of carcinoma. The origin could not be conclusively determined, as samples from the prostate and bladder yielded similar results. Therefore, further evaluation, including immunohistochemistry is necessary, and the case needs to be referred to a tertiary facility.

## DISCUSSION

Fournier's gangrene (FG) was named after Jean-Alfred Fournier, a dermatologist who first described a case in healthy young men in 1883. Many literatures use different names for this disease, such as overwhelming gangrene, gangrene fulminante de la verge, necrotizing fasciitis of genitalia, idiopathic gangrene, periurethral phlegmon, streptococcal gangrene, etc.<sup>1,2</sup> Fournier's gangrene is an acute fulminant mixed infection between aerobic and anaerobic microbes, affecting the perineum-genital region, with rapid progression, potentially being life-threatening.<sup>3</sup>

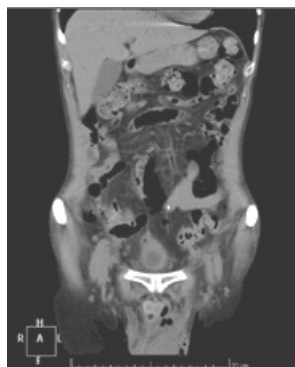Fournier's gangrene is a rare disease, and the exact incidence is unknown.<sup>1</sup> It can affect both sexes,

but it is more prevalent in men, with a ratio of approximately 10:1. This is attributed to better drainage through vaginal secretion. LGBT individuals, especially men with men, are at the highest risk. The source of infection is urogenital in most cases (45%), followed by perianal (33%) and cutaneous (21%).<sup>1,4</sup> Gender criteria applied from general cases in this instance

The literature reports that FG usually occurs in the fourth to seventh decades of life, with a mean age of 55.6 years. There is no difference in ethnicity regarding the incidence of FG. Fournier's gangrene mostly occurs in individuals with immunosuppressed conditions (HIV, malignancy, obesity, diabetes, immunosuppressant therapy), neuropathies, hypertension, renal and liver failure.<sup>1,3,4</sup> The sources of infection often come from urogenital, perianal, and cutaneous diseases. Trauma, surgery, urethral obstruction, urinary extravasation, and instrumentation of the perineal region may also lead to the disease. Immunocompromised is the most contributing factor that makes a host develop FG. Other risk factors include diabetes mellitus, malignancy, malnourishment, obesity, and alcoholism.<sup>5-7</sup> This case has age criteria in the seventh decade, combined with immunosuppressive conditions resulting from wasting syndrome due to advanced urogenital cancer.

Single or multiple microorganisms have been reported in several cases and literature, despite no correlation for the outcome. There are differences between literature that state *Proteus* and *E. coli* are the most common organisms isolated, while others include *Streptococcus*, *Pseudomonas*, *Klebsiella*, and *Clostridium*.<sup>7</sup> In this case, a culture of a single organism of *E. coli* bacteria was found.

As cancer replicates, tumors may outgrow the blood supply and infiltrate healthy tissues. This causes necrosis within the cancer and/or adjacent



**Figure 5.** Computerized tomography urogram.

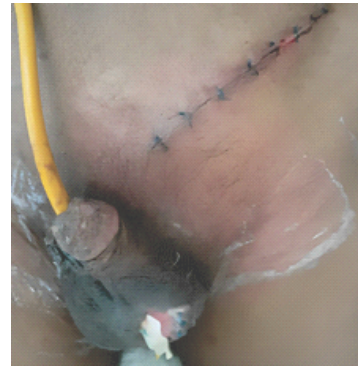healthy tissues, increasing the area of the tumors or tissues infected by microbes via hematogenous or direct inoculation.<sup>6</sup> The infection is often polymicrobial and may contain anaerobe pathogens, but it does not rule out the possibility of being a single microbial, as in this case. Furthermore, the infection and inflammation promote tissue destruction, causing impaired blood supply, hypoxia, and are responsible for micro-thrombosis of the tissue vessels. Facultative and obligatory anaerobes (e.g., *E. coli*, *Bacteroides fragilis*, and *Clostridium perfringens*) can easily grow. Bacteria that possess certain tissue-spreading factors may spread along the fatty tissue and fascial planes, leading to progressive cellulitis and potentially necrotizing fasciitis.<sup>7-8</sup>

Malignancy-induced FG typically presents with common features of FG compared with other etiologies. Pain and swelling in the genital-perineal area are observed in 85% of cases, peri-anal pain in about 10%, erythema in 35%, and skin necrosis in 85%. Less common findings include skin ulceration (10%), purulent discharge (35%), and crepitus (25%).<sup>1,2,7</sup> Fournier's gangrene commonly has a rapid onset, and bacteremia is considered the progression of necrosis through the fascial plane.<sup>1,2,7</sup> The typical criteria do not apply in this case because the patient presented with sudden scrotal pain without systemic symptoms such as fever, accompanied by an incarcerated hernia. As a result, Fournier's gangrene was not initially diagnosed. Subsequently, pus was found intraoperatively in the tunica dartos, spreading up to the Scarpa's fascia.

Fournier's gangrene is commonly a clinical diagnosis. A complete history taking and physical examination should include information on underlying etiologies, especially malignancy in urogenital, anorectal, skin, and soft tissues malignancies. A history of instrumentation in the anorectal and urogenital region should be taken. A thorough physical examination, including DRE, over 83% of patients demonstrated positive findings, palpable mass, purulent anal drainage.<sup>7</sup> A few months earlier, there was a history of manipulation of the patient's urogenital tract, including failed placement of a urethral catheter, leading to the performance of urethrotomy due to urethral stricture.

Laboratory evaluation for each patient should include a complete blood count, basic metabolic panel, and coagulation profile. For patients with signs of severe sepsis or shock, a complete metabolic panel, serum lactate, blood

cultures, and others are essential.<sup>7</sup> Radiography modalities for diagnosing FG include plain radiography, ultrasonography, CT scan, and MRI. CT has been proven to have greater specificity than plain radiography; the affected area gas can be detected.<sup>6</sup> Supporting examinations in this case that were found to be significant include leukocytosis, and an increase in urea and creatinine. However, radiological studies did not reveal specific images indicating infection in the scrotal fascia or the fascia of the abdominal wall.



**Figure 6.** Day-2 after debridement and herniorrhaphy.

Fournier's gangrene is a urological emergency, causing deaths due to the rapid progression of the infection, leading to septic shock and multiple organ failure. The current management guidelines involve the rapid initiation of broad-spectrum antibiotics, supportive management like IV fluids, and septic shock management if present, as well as aggressive surgical debridement. Cultures obtained before antibiotics are given, and as soon as the results are available, the antibiotic should be changed to be targeted due to the sensitivity of the bacteria. Before or after surgery, the patient should be closely monitored.<sup>7-8</sup>

A hyperbaric oxygen chamber is suggested to be adjuvant therapy for FG. It can inhibit anaerobic bacterial growth, prevent further tissue damage, and assist in tissue or wound healing. However, its use is still controversial due to recent studies failing to identify a clear benefit for patients.<sup>7</sup>

The Fournier's Gangrene Scoring Index (FGSI) is a scoring index for FG that is widely used in recent years. Factors that are included are body temperature, heart rate, respiratory rate, hematocrit, leukocyte count, and serum levels of sodium, potassium, creatinine, and bicarbonate. According to this scale, a score of >9 is associated with a 75%

mortality, while scores of  $<9$  correspond to a 78% probability of survival.<sup>7</sup> FG in this patient was well-managed with an excellent prognosis after treatment for nearly 14 days. The patient needs to be referred to a tertiary facility for further examination and management of their advanced urogenital cancer.

## CONCLUSION

In conclusion, the presented case underscores the multifaceted nature of Fournier's Gangrene, emphasizing the significance of a comprehensive diagnostic approach. The atypical manifestation of sudden scrotal pain in a patient with advanced urogenital cancer and an incarcerated inguinal hernia highlights the challenges in recognizing this potentially life-threatening condition.

The association with malignancy adds complexity to the diagnosis, necessitating a multidisciplinary collaboration for optimal patient care. The presence of masses in the prostate and bladder further emphasizes the need for a nuanced understanding of Fournier's Gangrene in the context of underlying urogenital malignancies.

Despite the initial diagnostic challenges, the case demonstrated the importance of timely intervention, including surgical debridement and antibiotic therapy. The patient's excellent prognosis after a 14-day hospital stay underscores the critical role of early diagnosis and comprehensive management in improving outcomes.

This case serves as a reminder to healthcare practitioners that Fournier's Gangrene may deviate from conventional presentations, especially in the presence of complicating factors such as advanced urogenital cancer. Vigilance, thorough assessments, and a collaborative approach are essential for navigating the complexities of this rare but potentially severe condition.

Ultimately, this case contributes to the evolving understanding of Fournier's Gangrene and emphasizes the need for ongoing research and awareness in the medical community to enhance diagnostic accuracy and optimize patient outcomes.

## REFERENCES

1. Arkoubi AY, Salati SA. Fournier's gangrene-Case report and a brief review. *Journal of Pakistan Association of Dermatologists*. 2015; 25(1): 44-51.
2. Sitepu ANR, Syafril S. Fournier Gangrene in Newly Diagnosed Diabetes Mellitus Patient: A Case Report. *Journal of Endocrinology, Tropical Medicine, and Infectious Disease (JETROMI)*. 2020 Nov 30; 2(4): 198-205.
3. Inácio MF, Lima RP, Neto SR, Lopes FA, Pantaroto M, de Sousa AV. Epidemiological study on Fournier syndrome in a tertiary hospital in Jundiaí-SP from October 2016 to October 2018†. *Journal of Coloproctology*. 2020 Jan 1; 40(1): 37-42.
4. Lin HC, Chen ZQ, Chen HX, He QL, Liu ZM, Zhou ZY, et al. Outcomes in patients with Fournier's gangrene originating from the anorectal region with a particular focus on those without perineal involvement. *Gastroenterology Report*. 2019 Jun 1; 7(3): 212-7.
5. Altarac S, Katuin D, Crnica S, Papeš D, Rajković Z, Arslani N. Fournier's gangrene: Etiology and outcome analysis of 41 patients. Vol. 88, *Urologia Internationalis*. 2012. p. 289-93.
6. Chernyadyev SA, Ufimtseva MA, Vishnevskaya IF, Bochkarev YM, Ushakov AA, Beresneva TA, et al. Fournier's Gangrene: Literature Review and Clinical Cases. *Urologia Internationalis*. 2018 Jul 1; 101(1): 91-7.
7. Mann AJ, Reinoso DB, Genuit T, Jimenez J. Fournier's Gangrene in the Setting of Underlying Carcinoma: A Case Report and Review of the Literature. *Cureus*. 2020 Sep 8.
8. Selvi I. Fournier's Gangrene without Organ Perforation Following Docetaxel: A Rare Urological Emergency Occurrence in a Patient with Metastatic Prostate Cancer. *Archives of Clinical Case Studies*. 2019 Sep 27; 1(5).