

# BUCCAL MUCOSAL GRAFT ONLAY TECHNIQUE FOR UPPER URETERIC AND UPJ STRICTURES

<sup>1</sup>Nerli RB, <sup>1</sup>Shreyas Rai, <sup>1</sup>Abhinay Jogula, <sup>1</sup>Keyur Patel, <sup>1</sup>Ashwin Bokare.

<sup>1</sup> Department of Urology, JN Medical College, KLE Academy of Higher Education & Research, JNMC Campus, India.

## ABSTRACT

**Objective:** In this paper we report our experience in the use of buccal mucosal grafts in the reconstruction of difficult upper ureteric and uretero-pelvic junction strictures. **Material & Methods:** We retrospectively looked at our hospital inpatient and outpatient records of all patients who underwent surgical treatment for benign upper ureteric strictures and ureteropelvic junction strictures. **Results:** During the study period a total of 22 patients with a mean age of  $32 \pm 6.07$  years underwent buccal mucosal graft repair. The mean length of the narrowing/stricture was  $6.40 \pm 1.44$  cm. **Conclusion:** Buccal mucosal onlay graft ureteroplasty is a suitable treatment option for long, complicated benign upper ureteric and select ureteropelvic junction strictures. It is technically simple and capable of providing optimum patency of ureter with good urinary drainage. It is safe and effective.

**Keywords:** Buccal mucosa, ureteric stricture, ureteropelvic junction stricture, graft, ureteroplasty.

## ABSTRAK

**Tujuan:** Pada penelitian ini kami melaporkan pengalaman kami dalam penggunaan cangkok mukosa bukal dalam rekonstruksi striktur persimpangan ureter-pelvis dan uretero-pelvis bagian atas yang sulit dilakukan. **Bahan & Cara:** Kami secara retrospektif melihat catatan rawat inap dan rawat jalan di rumah sakit kami dari semua pasien yang menjalani perawatan bedah untuk striktur ureter atas jinak dan striktur sambungan ureteropelvis. **Hasil:** Selama masa penelitian, total 22 pasien dengan usia rata-rata  $32 \pm 6.07$  tahun menjalani perbaikan cangkok mukosa bukal. Rerata panjang penyempitan/striktur adalah  $6.40 \pm 1.44$  cm. **Simpulan:** Ureteroplasti cangkok mukosa bukal merupakan pilihan pengobatan yang sesuai untuk striktur ureter atas jinak yang panjang dan rumit serta striktur sambungan ureteropelvis tertentu. Secara teknis sederhana dan mampu memberikan patensi ureter yang optimal dengan drainase urin yang baik. Ini aman dan efektif.

**Kata kunci:** Mukosa bukal, striktur ureter, striktur sambungan ureteropelvis, cangkok, ureteroplasti.

Correspondence: Rajendra B. Nerli; c/o: Department of Urology, JN Medical College, KLE Academy of Higher Education & Research, JNMC Campus, Nehru Nagar, Belagavi, Karnataka 590010, India. Mobile Phone: +91-9886616317. E-mail: rbnerli@gmail.com.

## INTRODUCTION

Oral mucosal grafts (OMGs) consist of nonkeratinized mucosa and is believed to have specialized and optimal vascular characteristics.<sup>1-2</sup> Oral grafts have a pan-laminar plexus. The oral mucosal grafts can be thinned, provided that a sufficient amount of deep lamina is carried to preserve the physical characteristics and not affect the vascular characteristics.<sup>3</sup> Buccal mucosal grafts (BMG) are OMGs that overly the buccinator muscle in the cheeks. BMGs are easy to harvest and handle, are resilient to infections, and are accustomed to a wet environment. As the BMG has a “wet epithelial” surface, it is believed that it has favourable characteristics for many cases of uroepithelial

reconstructive surgery. Over the last few decades, OMGs have become the new recommended source for urethral reconstruction.<sup>4</sup>

The buccal and lingual mucosae have similar tissue characteristics, including a thick epithelium, high content of elastic fibers, thin lamina propria, and high capillary density, which are beneficial for promoting revascularization. Using buccal mucosa as a tube or an onlay/inlay graft for the treatment of complex ureteral strictures has been reported. Somerville and Naude<sup>5</sup> carried out the feasibility of replacing a damaged segment of ureter with a free, non-pedicled, full thickness graft from buccal mucosa and the results showed that in all cases perfect viability of the graft was maintained and there was no evidence of graft shrinkage or of

loss of patency. Currently, buccal mucosa graft (BMG) has gained wide acceptance as a graft of choice for onlay ureteroplasty.

Several single case reports<sup>6-8</sup> and case series reports<sup>9</sup> have described the success of BMG onlay ureteroplasty. The follow-up was from 3 to 85 months with success rates of 71.4%-100%. The length of ureteral repair ranged from 1.5 cm to 11 cm. Kroepfl et al. reported the reconstruction of long ureteral strictures utilizing buccal mucosal patch grafts and omental wrapping in six patients.<sup>9</sup> All patients showed good functional outcomes at an intermediate-term follow-up.

## OBJECTIVE

In this paper we report our experience in the use of buccal mucosal grafts in the reconstruction of difficult upper ureteric and uretero-pelvic junction strictures.

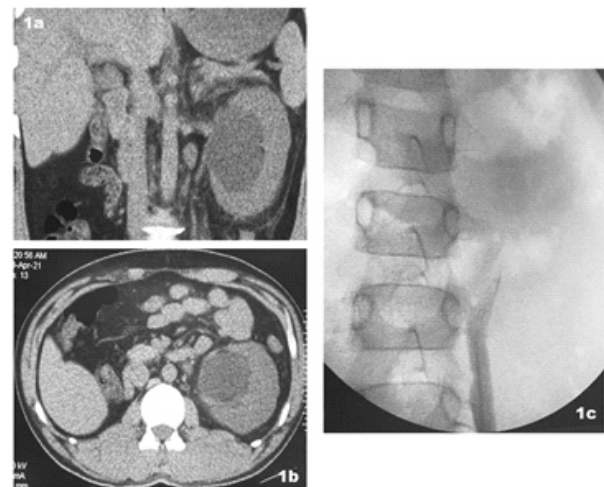
## MATERIAL & METHODS

We retrospectively looked at our hospital inpatient and outpatient records of all patients who underwent surgical treatment for benign upper ureteric strictures and ureteropelvic junction strictures during the period Jan 2015 till Dec 2020. This study was taken up with the permission granted from the Institutional/University ethical committee. The age, gender, symptoms and the physical findings of the patients was noted. Imaging records and films (Figure 1), histopathological reports were reanalysed. The long-term outcomes were also noted.

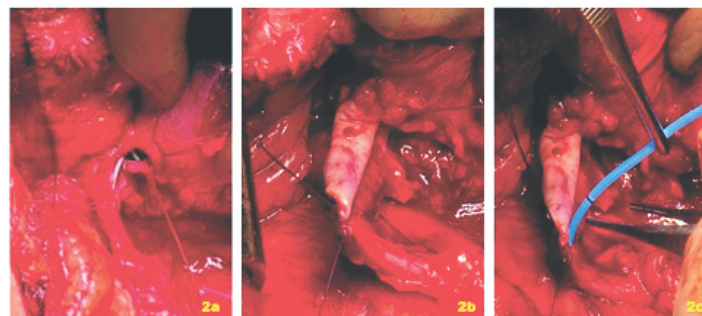
The patient was positioned in a supine position with an upward tilt on the side of the stricture and opposite leg flexed and tucked behind

the ipsilateral lower limb. An oblique lumbar incision was made extending from the tip of the 11<sup>th</sup> rib towards the umbilicus. The upper ureter and the ureteropelvic junction (UPJ) were approached extra-peritoneally. The ureteric/UPJ stricture was identified and the stricture was incised in their entire length with extension of the incision into the normal width ureter for 1 cm caudally and proximally to the stricture.

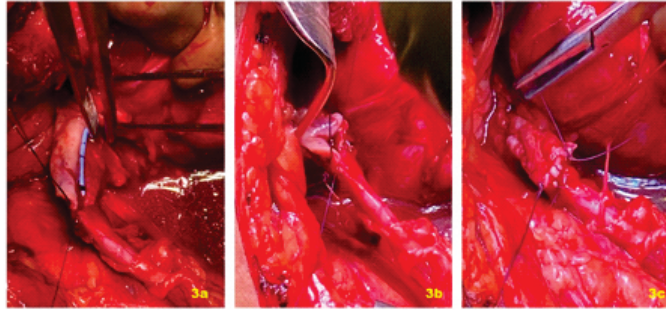
A buccal mucosal graft of roughly the same dimension was harvested by an assisting surgeon and thinned and shaped to appropriate size. The reconstructed ureter was stented with 6/8 Fr double J stent. The buccal mucosal graft was sutured into position with continuous 6/0 polyglactin (Vicryl) (Figure 2 & 3).



**Figure 1.** (a,b) CT scan shows left sided hydronephrosis with intra-renal pelvis (c) retrograde ureterogram shows complete cut-off at the level of proximal ureter.



**Figure 2.** (a) The strictured upper ureter and the UPJ opened widely so as to show a previously inserted DJ stent (b) A 6 cm buccal mucosal graft taken and sutured to the UPJ and upper ureter (c) A 8Fr. DJ inserted across the anastomotic site.



**Figure 3.** (a, b) The buccal mucosal graft being sutured at the UPJ and upper ureter (c) Anastomosis completed.

The omentum was mobilized and wrapped around the reconstructed ureteric/UPJ segment and tacked in place with absorbable sutures. The wound was drained with drainage tubes and the urinary bladder catheterized with a Foley catheter. The drain was removed 24 hours after the drain was nil for 24 hours. The catheter was removed after 10 days. The double J stent was removed after 6 weeks. The patients were followed up with appropriate antibiotics for a week. At the time of double J stent removal, a retrograde uretero-pyelogram was performed. A DTPA (diethylene triamino penta acetic acid) renogram was done 12-24 weeks after stent removal.

## RESULTS

During the study period a total of 22 patients (17 males and 5 females) with a mean age of  $32 \pm 6.07$  years underwent buccal mucosal graft repair of the proximal ureter and stenosis/stricture of the ureteropelvic junction. The aetiology of the strictures was iatrogenic in 15 (following ureterorenoscopy for the management of ureteric/renal pelvic calculi), following trauma in 2 and due to genito-urinary tuberculosis in 5 patients. The mean length of the narrowing/stricture was  $6.40 \pm 1.44$  cms. The strictures were located at ureteropelvic junction in 3, proximal ureter in 18 and involving both in one. In all the 4 patients with narrowing/stricture at UPJ, the renal pelvis was mostly intrarenal making it near impossible to perform a pyeloplasty. Radionuclide renograms showed poor function on the affected side in all patients.

The buccal mucosal grafts were harvested from healthy areas and were of sufficient length to bridge the gap in all the patients. Omental wrapping was performed in all. This was further strengthened by using retroperitoneal fat. There were no

intraoperative complications noted and none of the patients needed either intra or post-operative blood transfusions. Patients having strictures secondary to tuberculosis had increased intra-operative bleeding however none needed transfusions. Immediate post-operative period was uneventful in all and all patients voided well after removal of urethral catheters. Serum creatinine remained stable at 6 and 12 weeks after surgery. Radioisotope renograms done 12-16 weeks after surgery showed improvement in function on the affected sides in all patients with adequate drainage. Urine cultures remained sterile. All patients have shown stable serum creatinine levels, sterile urine cultures at 12 months follow-up. The mean follow-up was  $34.31 \pm 12.09$  months.

## DISCUSSION

An upper ureteral/UPJ stricture is characterized by a narrowing at the site of the stricture that causes a functional obstruction. As urinary drainage becomes restrained, the urine stagnates in the collecting system above the level of obstruction upto renal pelvis. This leads to pain, discomfort, nausea, vomiting, possibly to urinary tract infections or even renal failure if left untreated.<sup>10-12</sup> Short segment strictures of the proximal ureter and UPJ can be reconstructed surgically by primary excision and end-to-end anastomosis in the form of pyeloureteroplasty or ureteroureterostomy.<sup>13-14</sup>

However, if the stricture represents a long segment, then more advanced surgical techniques were required to provide a tension-free anastomosis and included procedures such as renal mobilization with and without nephropexy, ileal replacement of the ureter, transureteroureterostomy, ureterocalycostomy and auto-transplantation of the kidney.<sup>15</sup> Procedures such as auto-transplantation

**Table 1.** Clinical reports of using oral mucosal grafts.

Authors	Patients (n)	Graft	Length of graft	Follow-up	Donor site complications	Complications	Success rate (%)
Kroepfl et al. <sup>9</sup>	7	BMG	3-11	10-85	ND	Restenosis-2	71.4
Badawy et al. <sup>23</sup>	5	BMG	3.5-5	14-39	ND	none	100
Pandey et al. <sup>24</sup>	3	BMG	4-6	26-50	ND	none	100
Tsaturyan et al. <sup>25</sup>	5	BMG	2.5-5	26-52	ND	none	100
Ahn et al. <sup>26</sup>	3	BMG	2.5-6	5-26	none	none	100
Hefermehl et al. <sup>27</sup>	4	BMG	3-5	12-14	difficulty to whistle-1	none	100
Present series	22	BMG	5-9	12-60	None	none	100

require high expertise<sup>16</sup> and incorporation of a long bowel segment into the urinary tract is associated with severe metabolic and intestinal complications.<sup>17</sup>

The stricture portion of the upper ureter/UPJ is insufficient to effectively drain the system, but it could still provide an "ureteral plate" with adequate blood supply. An onlay repair could be performed using this plate. Recently, this technique of onlay ureteroplasty with grafts or flaps has been attempted by many reconstructive urologists and the outcomes appear to be highly encouraging. A graft needs to be hairless, easy to access and harvest, and be viable in a urinary environment so as to be suitable to be incorporated into the urinary tract. The oral mucosa is hairless, easily accessible, easy to harvest, and compatible with a wet environment. The common sites of oral mucosa graft (OMG) harvesting include the inner cheek or lip (buccal mucosa) and the lateral or ventral surface of the tongue (lingual mucosa). The buccal and lingual mucosae have the same tissue characteristics, including a thick epithelium, high content of elastic fibers, thin lamina propria, and high capillary density, which are beneficial for promoting revascularization.<sup>15</sup> Several recently published reports have shown good functional outcomes at an intermediate-term follow-up (Table 1). The length of ureteral repair has ranged from 1.5 cm to 11 cm.<sup>9,15</sup>

Harvesting of BMGs has been shown to be associated with some long-term donor site morbidities, such as perioral numbness, persistent difficulty with mouth opening, and latent parotid duct injury.<sup>18-19</sup> Controversy exists as to whether the buccal mucosa is a better graft than a lingual mucosa graft (LMG). Lumen et al.<sup>20</sup> demonstrated that LMG provided similar outcomes equivalent to BMG urethroplasty for anterior urethral stricture but with lower donor site morbidity. More bleeding is encountered when harvesting a LMG as the tongue is

more vascular than the cheek. LMG harvesting is technically easier than graft harvesting from the inner cheek as the tongue can be pulled out of the mouth.<sup>21</sup> However, morbidities after LMG harvesting, such as difficulty in mouth opening and persistent numbness of the donor site, were significantly less than those after BMG harvesting.<sup>20</sup>

Naude<sup>22</sup> initially reported on tabularised BMG interposition for the management of complex ureteral stricture in one patient with a traumatic loss of 4 cm of the middle ureter. Badawy et al.<sup>23</sup> reported on a series of 5 cases of proximal and middle ureteral strictures treated with tabularised grafts. The ureteral strictures had resulted from chronic inflammatory conditions or iatrogenic procedures, and the clinical and radiological results of tubular BMG were encouraging at a mean follow-up of 24 months. The vascularized ureteral adventitia was preserved after the excision of the diseased ureter in some cases, and the reconstructed ureter was wrapped with a pedicled piece of omentum in all cases to maintain a suitable blood supply.

In our series too, the length of the strictures was long and definitely needed long grafts. The harvesting of grafts was easy and of desired length. The uretero-mucosal anastomosis was easily performed and the anastomosis covered with pedicled omental grafts. The outcome in our series was good during the mean follow-up period of 34.31±12.09 months.

## CONCLUSION

In conclusion long-segment stricture of the proximal ureter and ureteropelvic junction is often a treatment dilemma for most urologists. Ureteroplasty using autologous patch grafts is an optional surgical technique, namely, an onlay ureteroplasty procedure with or without an



augmented anastomotic technique. Buccal mucosal graft has been the most commonly used graft in these repairs. The procedure is safe and effective and both short and intermediate term outcomes are encouraging.

## REFERENCES

- Humby, G. One-stage operation for hypospadias, *Br J Surg.* 1941; 29: 84–92.
- Memelaar, J. Use of bladder mucosa in a one stage repair of hypospadias. *J Urol.* 1947; 58: 68–73.
- Virasoro R, Jordan GH and McCammon KA. Surgery for benign disorders of the penis and urethra. In Partin AW, Dmochowski RR, Kavoussi LR and Peters CA Eds. *Campbell-Walsh-Wein Urology.* 12 ed Elsevier. Philadelphia. 2020. p 1807.
- Bhargava and Chapple, Bhargava S. Chapple CR: Buccal mucosal urethroplasty: is it the new gold standard?. *BJU Int.* 2004; 93: 1191–1193.
- Somerville, J.J.F., Naude, J.H. Segmental ureteric replacement: An animal study using a free non-pedicled graft. *Urol. Res.* 1984; 12: 115–119.
- V. Agrawal, V. Dassi, and M. G. Andankar. Buccal mucosal graft onlay repair for a ureteric ischemic injury following a pyeloplasty. *Indian Journal of Urology.* 2010; 26: 120–122.
- S. Sadhu, K. Pandit, M. K. Roy, and S. K. Bajoria. Buccal mucosa ureteroplasty for the treatment of complex ureteric injury. *The Indian Journal of Surgery.* 2011; 73: 71-72.
- V.P. Sabale, N. Thakur, S.K. Kankalia, and V.P. Satav. A case report on buccal mucosa graft for upper ureteral stricture repair. *Urology Annals.* 2016; 8: 474-77.
- D. Kroepfl, H. Loewen, V. Klevecka, and M. Musch. Treatment of long ureteric strictures with buccal mucosal grafts. *BJU International.* 2010; 105: 1452-55.
- R. B. Knight, S.J. Hudak, and A.F. Morey. Strategies for open reconstruction of upper ureteral strictures. *The Urologic Clinics of North America.* 2013; 40: 351–361.
- S. I. Tyrantzis and N. P. Wiklund. Ureteral strictures revisited trying to see the light at the end of the tunnel: a comprehensive review. *Journal of Endourology.* 2015; 29: 124–136.
- N.M. Buffi, G. Lughezzani, R. Hurle et al. Robot-assisted surgery for benign ureteral strictures: experience and outcomes from four tertiary care institutions. *European Urology.* 2017; 71: 945–951.
- N. Buffi, A. Cestari, G. Lughezzani et al. Robot-assisted uretero-ureterostomy for iatrogenic lumbar and iliac ureteral stricture: technical details and preliminary clinical results. *European Urology.* 2011; 60: 1221–1225.
- M. Colicchia, P. Beltrami, M. Soligo et al. Endourological management of benign ureteral stricture: less is more?. *European Urology Supplements.* 2019; 18(1): e1480.
- Xiong S, Wang J, Zhu W, et al. Onlay repair technique for the management of ureteral strictures: A comprehensive review. *Biomed Research Int* 2020.
- G. Tran, K. Ramaswamy, T. Chi, M. Meng, C. Freise, and M.L. Stoller. Laparoscopic nephrectomy with auto-transplantation: safety, efficacy and long-term durability. *The Journal of Urology.* 2015; 194: 738–743.
- A. Kocot, C. Kalogirou, D. Vergo, and H. Riedmiller. Long-term results of ileal ureteric replacement: a 25-year single-centre experience. *BJU International.* 2017; 120: 273–279.
- D. N. Wood, S. E. Allen, D. E. Andrich, T. J. Greenwell, and A. R. Mundy. The morbidity of buccal mucosal graft harvest for urethroplasty and the effect of nonclosure of the graft harvest site on postoperative pain. *The Journal of Urology.* 2004; 172: 580–583.
- G. Barbagli, S. Vallasciani, G. Romano, F. Fabbri, G. Guazzoni, and M. Lazzeri. Morbidity of oral mucosa graft harvesting from a single cheek. *European Urology.* 2010; 58: 33–41.
- N. Lumen, S. Vierstraete-Verlinde, W. Oosterlinck et al. Buccal versus lingual mucosa graft in anterior urethroplasty: a prospective comparison of surgical outcome and donor site morbidity. *The Journal of Urology.* 2016; 195: 112–117.
- A. K. Sharma, R. Chandrashekar, R. Keshavamurthy et al. Lingual versus buccal mucosa graft urethroplasty for anterior urethral stricture: a prospective comparative analysis. *International Journal of Urology.* 2013; 20: 1199–1203.
- J. H. Naude. Buccal mucosal grafts in the treatment of ureteric lesions. *BJU International,* 1999; 83: 751–754.
- A. A. Badawy, A. Abolyosr, M. D. Saleem, and A. M. Abuzeid. Buccal mucosa graft for ureteral stricture substitution: initial experience. *Urology.* 2010; 76: 971–975.
- A. Pandey, R. Dican, J. Beier, and H. Keller. Buccal mucosal graft in reconstructive urology: uses beyond urethral stricture. *International Journal of Urology.* 2014; 21: 732–734.
- A. Tsaturyan, K. Akopyan, A. Levonyan, and A. Tsaturyan. Long ureteric stricture replacement by buccal mucosa graft: an Armenian experience case series report. *Central European Journal of Urology.* 2016; 69: 217–220.
- J. J. Ahn, M. E. Shapiro, J. S. Ellison, and T. S. Lendvay. Pediatric robot-assisted redo pyeloplasty with buccal mucosa graft: a novel technique. *Urology.* 2017; 101: 56–59.
- L. J. Hefermehl, S. Tritschler, A. Kretschmer et al. Open ureteroplasty with buccal mucosa graft for long proximal strictures: a good option for a rare problem. *Investigative and Clinical Urology.* 2020; 61: 316–322.