

# SUCCESSFUL TRANSURETHRAL RESECTION OF ANTERIOR URETHRAL VALVE IN CHILDREN : A CASE REPORT

<sup>1</sup>Fariz Kemal Akbar, <sup>1</sup>Kurnia Penta Seputra, <sup>1</sup>Pradana Nurhadi.

<sup>1</sup> Department of Urology, Faculty of Medicine/University of Brawijaya, Saiful Anwar General Hospital, Malang.

## ABSTRACT

**Objective:** This case report will present transurethral resection of double anterior urethral valves in tertiary hospital. **Case(s) Presentation:** A three-year-old boy who complained of a poor stream of urine and discomfort during micturition. From the radiological examination, the main finding was found on ultrasound (USG), with thickening of the bladder wall without upper tract abnormality. On panendoscopy, we found double anterior urethral valves at bulbar part and trabeculation in bladder. **Discussion:** The resection of the valves was performed and achieved an excellent result included normal stream of urine and there was no discomfort during micturition. **Conclusion:** Anterior Urethral Valve is a rare case that can be caused a lower urinary tract obstruction. A good understanding of AUV's radiological and endoscopic anatomy is required to differentiate it from other diseases, essential to prevent further injury, and also to decide for appropriate management.

**Keywords:** Anterior Urethral Valve, Congenital Anomaly, Urinary Obstruction

## ABSTRAK

**Tujuan:** Laporan kasus ini mempresentasikan tindakan reseksi katup uretra anterior ganda pada rumah sakit rujukan. **Presentasi Kasus:** Anak laki-laki berusia 3 tahun yang mengeluhkan aliran urin yang lemah dan ketidaknyamanan saat berkemih. Dari pemeriksaan radiologi ultrasound (USG), ditemukan penebalan dinding kandung kemih tanpa kelainan saluran kemih bagian atas. Pada panendoskopi, ditemukan katup uretra anterior ganda di bagian bulbar dan trabekulasi pada kandung kemih. **Diskusi:** Reseksi katup telah dilakukan dan mencapai hasil yang sangat baik, termasuk aliran urin yang normal dan tidak ada ketidaknyamanan selama berkemih. **Simpulan:** Katup Uretra Anterior merupakan kasus langka yang dapat menyebabkan obstruksi saluran kemih bagian bawah. Pemahaman yang baik tentang anatomi, gambaran radiologis dan endoskopi AUV diperlukan untuk membedakannya dari penyakit lain, penting untuk mencegah cedera lebih lanjut, dan juga untuk memutuskan manajemen yang tepat.

**Kata Kunci:** Katup Uretra Anterior, Kelainan Kongenital, Obstruksi Saluran Kemih

Correspondence: Kurnia Penta Seputra; c/o: Departement of Urology, Faculty of Medicine/University of Brawijaya, Saiful Anwar General Hospital. Jl. Jaks Agung Suprpto No.2 Klojen, Kota Malang, Jawa Timur 65112. Indonesia. Phone: +6281944995539. Fax: +62341333030. Email: uropnt.fk@ub.ac.id

## INTRODUCTION

The urethral valve is a congenital anomaly that causes lower urinary tract obstruction. The most common of which is the posterior urethral valve (PUV). The anterior urethral valve (AUV) is a congenital defect that is uncommon but well-known. Semilunar folds arise from the anterior urethral floor to form AUVs. Posterior urethral valve (PUV) being the more frequent (with a reported incidence of 1 in

3000 to 8000 live births) cause than the anterior urethral valve are the most common. In comparison, AUV is 15–30 times less common than posterior urethral valves. It can occur as an isolated entity or, in association with a urethral diverticulum, probably representing a spectrum of the disease.<sup>1-2</sup>

While a number of hypotheses exist, the precise etiology of AUVs has not been well studied. Incomplete hypospadias, an aborted first-trimester attempt at urethral replication, defective

synchronization between the glandular and penile urethra, incomplete focal corpus spongiosum growth, and an inconsistency in developed urethral tissue resulting in a residual valve and cystic urethral glandular dilation are all possible triggers.<sup>2-4</sup>

AUV detection and treatment are also difficult to come by, regardless of the etiology. The signs can range from a high-grade lower urinary tract obstruction (LUTO) in utero to a late diagnosis after symptoms such as urinary incontinence, a sluggish stream, a ventral bulge, or urinary tract infections. As a result, the diagnosis is often skipped, resulting in a high level of infection which is critical in determining whether or not a diagnostic voiding cystourethrogram (VCUG) can be obtained.<sup>2</sup>

Although endoscopic management is the first line of treatment following diagnosis, followed by open restoration, little is known about the long-term prognosis and outcomes of patients with AUVs. Despite the fact that comparisons and evidence from PUV patients have been made and extrapolated, the two disease pathologies remain distinct.<sup>2</sup>

AUVs appear in a variety of ways, depending on the degree of obstruction and the patient's age. It can take a long time before you have a diagnosis, and it can also show up in adulthood. The most frequent symptoms at presentation include dribbling urine, a low urinary stream, and a UTI or urosepsis. A penile mass, which represents a dilated proximal urethra or diverticulum, can be found in rare cases. Although longitudinal transpenile ultrasound has been used to diagnose the valve tissue, VCUG remains the imaging gold standard in diagnosing AUV.<sup>3,5</sup>

This case will discuss a patient with anterior urethral valve undergo resection.

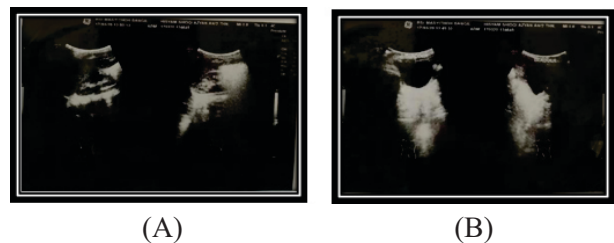
### CASE(S) PRESENTATION

The patient's parents complained that their son Male 3rd years old was uncomfortable / fussy during micturition. Complaints have been felt since approximately 1.5 years ago. Complaints are accompanied by a weak radiance during urination and sometimes dripping. The patient's parents only realized this complaint when the patient was not using a pampier (baby mat). In March 2020 the patient was taken to primary health care. After doing urological examination and laboratory findings, the patient was diagnosed with a urinary tract infections (UTI), and took antibiotics for several weeks there was no improvement. One month later the patient

was circumcised, because he was diagnosed with phimosis, but the complaints persisted.

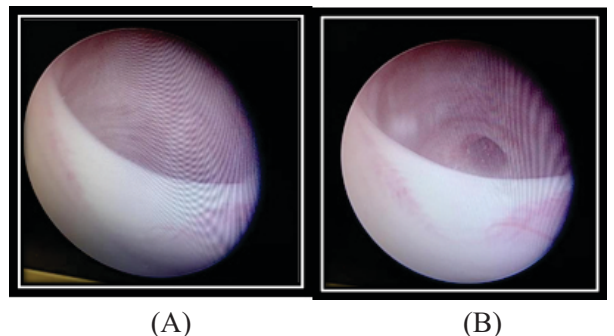
Last December 2020, the patient's parents brought their son back to a private hospital, because complaints were permanent. The patient was subjected to a Urological ultrasound examination by a surgeon specialist and was referred to Malang private hospital. History of hematuria was denied, history of expulsion of stones was denied, history of trauma was denied. History of jaundice, asthma, and allergies was denied. Patients are twins and their twins do not have the same complaint. Operation History: On April 20, 2020 the patient was circumcised at the Pandaan private hospital. Birth History: Born by sectio caesarea (SC) in a private hospital with a weight of 2.550 grams.

No remarkable physical examination in this patient. The patient has circumcised and spontaneous micturition is achieved. From Ultrasound (USG) at March, 3rd 2020, with thickening of the bladder wall without upper tract abnormality, only cystitis was found (Figure 1).



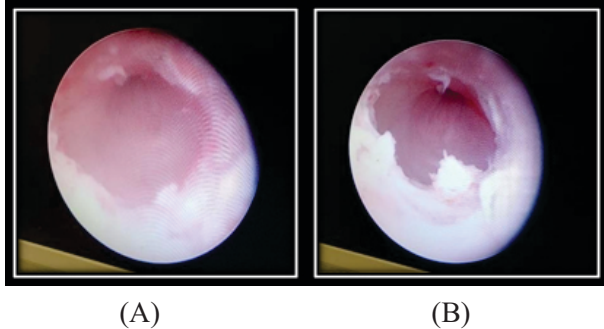
**Figure 1.** (A) Right and left kidney within normal limits, (B) Thickening of the bladder wall.

On cystoscopy, using pediatric cystoscopy sheaths 11Fr, we found double anterior urethral valves at bulbar part and trabeculation in bladder (Figure 2).



**Figure 2.** (A) Distal Anterior Urethral Valve, (B) Proximal anterior urethral valve

Resection of the urethral valve is attempted to the patient and excellent result has been achieved without further symptoms and complications. (Figure 3)



**Figure 3.** (A) Resection Distal Anterior Urethral Valve, (B) Resection Proximal Anterior Urethral Valve.

## DISCUSSION

An AUV is a fold in the urethral mucosa that is usually found around the ventral surface of the urethra. During micturition, the valve or fold rises and flattens against the urethra's dorsal side, causing obstruction. On endoscopy, the majority of valves appear semilunar (70%), while the remaining 30% will mimic an iris.<sup>4</sup>

The AUV's location varies as well. The bulbar urethra is the most popular site, accounting for 40% of cases. The penile urethra and penoscrotal junction account for 30% of the cases. Although many hypotheses exist in the literature, the etiology of these valves is unclear. A failed alignment of the glanular and penile urethra, an aborted attempt at urethral replication, inadequate hypospadias, an inconsistency of tissue development in the growing urethra that results in a valve-like tissue residual, or intrauterine obstruction are some of the causes. The diverticulum may form as a result of either incomplete urethral plate fusion or failure of the corpus spongiosum to fully develop. Since these two entities are often used together (one-third of the time), it's uncertain if the valve or the diverticulum is the main lesion.<sup>6-7</sup>

In this case, the unique was the anterior urethral valve was found alone without other anomalies. No hypospadias was detected in this case. No physical examination or USG examination was found also. The only anterior urethral valve is rare to stand alone. The clinical manifestation is highly variable and depends on the age of the patient and

degree of obstruction. It may present with severe obstruction manifestation and the complication itself. It is a posteriorly directed semilunar fold and arises from the anterior urethra. It can mimic an anterior urethral diverticulum, but the posterior lip is absent in the valve.<sup>3,5</sup>

Firlit et al. defined the most widely used classification scheme in 1978, which distinguishes the AUV into four forms based on the degree of obstruction as shown on VCUG. There is slight proximal urethral distension in Type I, and the bladder and upper urinary tract are not involved. Increased urethral distention and an accompanying urethral diverticulum characterize Type II. There is no involvement of the bladder or upper urinary tract. Mild bladder trabeculation and ureteral ectasia with low-grade VUR are seen in Type III, in comparison to the Type II findings. In Type IV, there is extreme proximal urethral dilatation, a urethral diverticulum, severe bladder trabeculation, high-grade VUR, and marked hydronephrosis. Firlit's classification scheme in the case of type III.<sup>7-8</sup>

Treatment for AUV varies based on whether or not a diverticulum is present, as well as other abnormalities. Endoscopic valve ablation is the preferred therapy for an isolated AUV. Transurethral resection is the preferred treatment option in the presence of a thin diverticulum with sufficient spongiosum. In this case, the resection give best result and no further complication. If treatment is not feasible, exteriorization of the urethra can be performed proximal to the valve.<sup>9-10</sup>

## CONCLUSION

Anterior Urethral Valve is a rare case that can be caused a lower urinary tract obstruction. In children who have UTIs, a decreased urinary stream, or obstructive symptoms, AUV should be treated as a possible cause of lower urinary tract obstruction. A good understanding of AUV's radiological and endoscopic anatomy is required to differentiate it from other diseases, essential to prevent further injury, and also to decide for appropriate management. If left untreated, these patients can suffer renal failure. Endoscopic ablation or resection will effectively cure the majority of these valves.

## REFERENCES

1. Cruz-Diaz O, Salomon A, Rosenberg E, Moldes JM, de Badiola F, Labbie AS, Gosalbez R, Castellan MA. Anterior urethral valves: not such a benign condition.

- Frontiers in pediatrics. 2013 Nov 8; 1: 35.
2. Sheth KR, White JT, Bilgutay AN, Seth A, Mittal AG. Anterior urethral valves—A rare but challenging congenital pathology. *Journal of pediatric urology*. 2020 Oct 1; 16(5): 585-e1.
  3. Keihani S, Kajbafzadeh AM. Concomitant anterior and posterior urethral valves: a comprehensive review of literature. *Urology*. 2015 Jul 1; 86(1): 151-7.
  4. Prakash J, Dalela D, Goel A, Singh V, Kumar M, Garg M, et al. Congenital anterior urethral valve with or without diverticulum: a single-centre experience. *J Pediatr Urol* 2013; 9(6 Pt B): 1183e7.
  5. Sharma A, Chaudhari R, Andankar M, Pathak H. Anterior urethral valve, a rare cause of bilateral vesicoureteral reflux in a two year old boy: A case report and a review of the literature. *Ped Urol Case Rep*. 2016 Apr 4; 3(3): 56-62.
  6. Parmar JP, Mohan C, Vora MP. Anterior urethral valve: a rare but an important cause of infravesical urinary tract obstruction. *Polish journal of radiology*. 2016; 81: 209.
  7. Routh JC, McGee SM, Ashley RA, Reinberg Y, Vandersteen DR. Predicting renal outcomes in children with anterior urethral valves: a systematic review. *The Journal of urology*. 2010 Oct; 184(4S): 1615-9.
  8. Singh DV, Taneja R. Anterior urethral valves without diverticulae: A report of two cases and a review of the literature. *Congenital anomalies*. 2014 May; 54(2): 120-2.
  9. Farmakis SG, Herman TE, Siegel MJ. Congenital anterior urethral valves: imaging diagnosis and management. *Journal of Perinatology*. 2014 Sep; 34(9): 726-8.
  10. Reddy D. Anterior urethral valve—a commonly misdiagnosed entity in adolescent boys. *Urology*. 2020 Jun 1; 140: 159-61.