

THE EFFECT OF SUKUN LEAF (*ARTOCAPTUS ALTILIS*) EXTRACT ON RENAL ISCHEMIA/REPERFUSION INJURY IN WISTAR RATS WITH PARAMETER OF KIDNEY HISTOPATHOLOGICAL FINDINGS SERUM CYSTATIN-C AND SERUM CYSTATIN-C

¹Safendra Siregar, ¹Max Stevanus, ¹Bambang S Nugroho.

¹Department of Urology, Faculty of Medicine/University of Padjadjaran, Hasan Sadikin General Hospital, Bandung.

ABSTRACT

Objective: To determine the effects breadfruit leaf extract (*Artocaptus altilis*) in Wistar rats, which had induced renal ischemic-reperfusion injury, with evaluation of serum cystatin C level and kidney histopathologic findings. **Material & Methods:** A total of 30 Wistar rats, three groups of ten, were included in the study and were performed in Bandung Eijkman Animal Laboratory. In group I (sham group), a right nephrectomy was done. In group II (control), a right nephrectomy was also done and the left renal pedicles were occluded for 60 minutes and reperused for 60 minutes. In group III (treatment), the treatment was equal with group II, and breadfruit leaf extract (4.75%) was administered intraperitoneally. At the end of the study, a left nephrectomy was performed on all groups. Afterward, serum cystatin C levels and kidney histopathological findings of all rats were examined. Data were analyzed by an unpaired numerically comparative analysis with SPSS 20.0 software. **Results:** The mean of serum Cystatin C in group I was 3183.2 ± 680.9 pg/dL, group II was 3776.4 ± 326.7 pg/dL, and group III was $3492.7 \pm 1.326.7$ pg/dL. The mean of histopathology renal score was also assessed, group I was 4.4 ± 0.52 , group II was 8.6 ± 0.84 , and group III was 6.3 ± 1.70 . Comparative test of serum cystatin C level, using ANOVA test and Benferroni post hoc test, in the treatment group has a p-value of > 0.05 , it showed that there were no significant differences on the value of cystatin C level on the treatment group. In correlation test of renal histopathology score, using Kruskal-Wallis test and Mann-Whitney post hoc test has a p-value of < 0.05 , therefore there were significant differences on the mean value of renal histopathology score in the treatment group, with Eta correlation coefficient 0.847. **Conclusion:** The beneficial effects of breadfruit leaf extract can be attributed to its protective effects on renal cells damage. This treatment has an important role in reducing renal injury resulting from renal ischemia-reperfusion. However, breadfruit leaf extract did not significantly improve renal function based on serum cystatin C level.

Keywords: *Artocaptus altilis*, renal ischemia-reperfusion injury, cystatin c, histopathology, kidney.

ABSTRAK

Tujuan: Mengetahui pengaruh ekstrak daun sukun (*Artocaptus altilis*) pada tikus Wistar yang telah diinduksi cedera iskemik reperfusi ginjal, dengan evaluasi kadar serum cystatin C dan temuan histopatologi ginjal. **Bahan & Cara:** Sebanyak 30 ekor tikus Wistar, tiga kelompok terdiri dari sepuluh ekor, diikutsertakan dalam penelitian dan dilakukan di Laboratorium Hewan Eijkman Bandung. Pada kelompok I dilakukan nefrektomi kanan. Pada kelompok II juga dilakukan nefrektomi kanan dan pedikel ginjal kiri dioklusi selama 60 menit dan reperfusi selama 60 menit. Pada kelompok III, perlakuan sama dengan kelompok II, yaitu pemberian ekstrak daun sukun (4.75%) secara intraperitoneal. Pada akhir penelitian dilakukan nefrektomi kiri pada pada semua kelompok. Setelah itu, kadar serum cystatin C dan temuan histopatologi ginjal semua tikus diperiksa. Data dianalisis dengan analisis komparatif numerik tidak berpasangan dengan software SPSS 20.0. **Hasil:** Rerata serum cystatin C pada kelompok I adalah 3183.2 ± 680.9 pg/dL, kelompok II 3776.4 ± 326.7 pg/dL, dan kelompok III $3492.7 \pm 1.326.7$ pg/dL. Rerata skor histopatologi ginjal juga dinilai, kelompok I 4.4 ± 0.52 , kelompok II 8.6 ± 0.84 , dan kelompok III 6.3 ± 1.70 . Uji perbandingan kadar serum cystatin C, menggunakan uji ANOVA dan uji post hoc Benferroni, pada kelompok perlakuan memiliki nilai $p > 0.05$, hal ini menunjukkan tidak terdapat perbedaan yang signifikan nilai kadar cystatin C pada kelompok perlakuan. Pada uji korelasi skor histopatologi ginjal, uji Kruskal-Wallis dan uji post hoc Mann-Whitney, memiliki nilai $p < 0.05$ sehingga terdapat perbedaan yang signifikan pada nilai rata-rata skor histopatologi ginjal pada kelompok perlakuan, dengan korelasi Eta koefisien 0.847. **Simpulan:** Efek menguntungkan dari ekstrak daun sukun dapat dikaitkan dengan efek perlindungannya pada kerusakan sel ginjal. Perawatan ini memiliki peran penting dalam mengurangi cedera ginjal akibat iskemia-reperfusi ginjal, namun, ekstrak daun sukun tidak secara signifikan meningkatkan fungsi ginjal berdasarkan kadar serum cystatin C.

Kata Kunci: *Artocaptus altilis*, cedera iskemia-reperfusi ginjal, cystatin C, histopatologi, ginjal.

INTRODUCTION

In Indonesia, numbers of chronic kidney disease patients has become a devastating medical, social, and economic problem for patients and their families. There are few renal diseases aetiology that can lead to renal ischemia-reperfusion resulting acute kidney injury (AKI), associated with high morbidity and mortality rates in human patients.¹ Acute renal failure is one of complication caused by decreased perfusion or blood flow resulted from several clinical problems, like, hemorrhagic shock, cardiac arrest, renal surgery, vascular surgery, etc.² Renal ischemia causes the depletion of cell energy, accumulation of intracellular sodium, reactive calcium and oxygen, activation of some enzymes, including protease, nitric oxide synthase (NOS), phospholipase and endonuclease, causing cell damage and death. Returning blood flow to already ischemic organs is crucial in preventing tissues death. However, the reperfusion itself causes a secondary local damage resulting from an acute inflammatory response which involves a tissue infiltration by the activity of both leucocyte and platelet. This tissue damage is mediated by imbalance between nitric oxide and superoxide.³⁻⁵

To assess more early tissue damage levels, there are several different useable biomarkers, one of which is the cystatin C levels both in blood and in urine. Cystatin C is an endogenous substance alternative which has been proposed years ago, because it has an ideal character as a GFR estimate. Some researches disclosed that protein is a better parameter in diagnosing renal dysfunction.⁵⁻⁶

Breadfruit (*Artocarpus altilis*) is known in Indonesia as one of the alternative source of carbohydrate. In addition, these breadfruit plants have several parts such as fruit, leaves, stems, and flowers that are believed to have beneficial effects on health. The leaves have active ingredients such as saponins, polyphenols, hydrocyanic acids, acetylcholine, tannins, riboflavin, phenol, quercetin, and champorol.⁷ Quercetin is one of the compounds of the flavonoid group that has antioxidant and anti-inflammatory effects. Polyphenols are also reported to have strong antioxidant effects.⁷

Quercetin is an antioxidant with the strongest antioxidant activity against free radicals of hydroxyl and peroxy, as well as superoxide anions.

NO levels can be reduced by reaction with free radicals, superoxide anions, and ends in tissue damage. Several studies on quercetin bioflavonoid suggest that treatment with quercetin in I/R injury can decrease destructive superoxide anion levels, and maintain cytoprotective NO levels. Reintroduction of oxygen after tissue reperfusion may result in increased production of superoxide and hydrogen peroxide sharply. In this condition, quercetin in Sukun leaf can decrease destructive superoxide anion content, and maintain cytoprotective levels of NO.^{3,7,8}

From these facts, we investigated the effect of breadfruit leaf extract in renal ischemic reperfusion injury, based on cystatin-C serum biomarker and histopathologic features parameters.

OBJECTIVE

Therefore, this research would determine the effect of Sukun leaf extract on renal ischemia/reperfusion injury by assessing the parameters of renal tissue damage, represented by cystatin C level and histopathological picture of kidney.

MATERIAL & METHODS

The present research would be carried out at Bandung Eijkman's veterinary laboratory, Anatomic Pathology and Clinic Pathology laboratory, Division of Urologic Surgery, FKUP/RSHS Bandung, from April to June 2017.

The research was laboratory-based preliminary research, substantially falling into a basic research of male wistar mice, 250-300 g weight. The research design used was experimental research, by determining cystatin C levels and histopathology in wistar mice treated with a left nephrectomy (guze). The research findings were then analyzed statistically by an unpaired numeric comparative analysis (guze).

Treatment was performed by anesthesia and an injection of ketamine 75 mg/kg intraperitoneal. The mice were divided into three groups, each 10 mice. In group I (sham group), a right nephrectomy was performed. In group II (control), a right nephrectomy was performed followed by an occlusion on left renal pedicle for 60 minutes and

perfusion was performed for 60 minutes.⁹⁻¹¹ To group III (treatment) the same treatment was performed as in group II, plus administration of 4.75% sukun leaf extract, given intraperitoneally before the operation. Toward the end of the research, a left nephrectomy was performed on the mice to determine the value of cystatin C levels and anatomic histopathology in wistar mice treated with nephrectomy.^{7,11,12}

The biomarker used in the present research to assess renal damage was cystatin C. It is a protein derived from a chain 120 amino acid and produced by a majority of cell nucleus. The gene for cystatin C synthesis is in chromosome 20. Cystatin C is contained in a systemic circulation at a high concentration and considered an important extracellular inhibitor of protease sistei.¹³⁻¹⁴

Some studies have revealed that cystatin C is more sensitive than serum creatine in identifying decreases in renal function. In addition, cystatin C is not affected by inflammatory process, sex, diet, and nutrient status. However, given that the substance is relatively new as a biomarker of the decrease of renal function, less studies have been conducted on it.¹³⁻¹⁴

Left kidney was fixated by formalin and placed in paraffin and colored by hematoxylin-eosin (HE). All samples were assessed by a single anatomic pathologist. The parameters assessed were glomerular atrophy and edema, tubular morphologies, and interstitial morphologies.^{7,15}

Statistical analysis by one-way analysis of variance (ANOVA) and Kruskal-Wallis test, followed by Benferroni and Mann-Whitney test using SPSS software to compare Cystatin C serum levels and histopathological findings between groups. P values<0.05 were statistically significant.

RESULTS

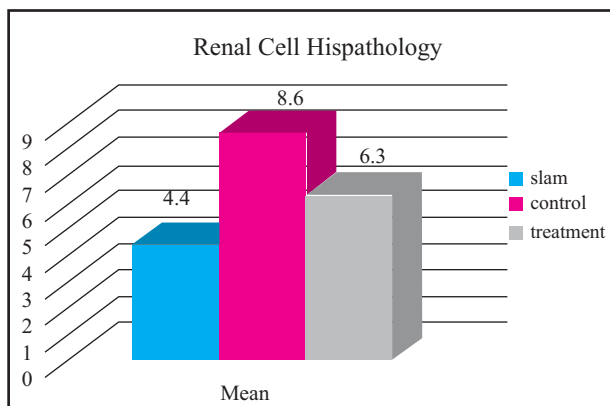


Figure 1. Renal cell histopathology

The figure above displays the mean necrosis of tubular renal cells of renal ischemia/reperfusion in wistar mouse. The highest mean renal cells histopathology was 10 at control group (group treated with a right nephrectomy followed by an occlusion on left renal pedicle for 60 minutes and perfusion was performed for 60 minutes), i.e. 8.6 ± 0.84 , the maximum value being 10 and minimum value 7. The lowest mean renal cells histopathology was at sham group (group with not treatment at all), i.e. 4.4 ± 0.52 , the maximum value being 5 and minimum value 4. For treatment group (group treated with a right nephrectomy followed by an occlusion on left renal pedicle for 60 minutes and perfusion was performed for 60 minutes, plus administration of 4.75% Sukun leaf extract), mean value was 6.3 ± 1.70 , the maximum value being 9 and minimum value 4.

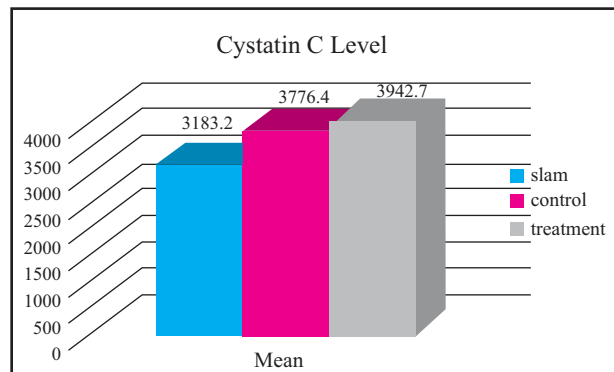


Figure 2. Cystatin C Level.

The figure above displays the mean cystatin C levels of renal ischemia/reperfusion in wistar mouse. The highest mean cystatin C kevels of renal ischemia/reperfusion in wistar mouse was at treatment group (group treated with a right nephrectomy followed by an occlusion on left renal pedicle for 60 minutes and perfusion was performed for 60 minutes, plus administration of 4.75% Sukun leaf extract), i.e. $3.942.70 \pm 326.75$, the maximum value being 4.485.00 and minimum value 3.378.00. The lowest mean cystatin C level was at sham group (group with not treatment at all), i.e. 3.183 ± 680.86 , the maximum value being 1.861.00 and minimum value 3.952.00. For control group (group treated with a right nephrectomy followed by an occlusion on left renal pedicle for 60 minutes and perfusion was performed for 60 minutes), mean value was $3.776.40 \pm 326.74$, the maximum value being 4.231.00 and minimum value 3.094.00.

The test was performed to evaluate the correlation between score of renal cell histopathology in at least a pair of group. The data renal cell histopathology didn't fit a normal distribution according to Kolmogorov-Smirnov test. Therefore, a non-parametric test of Kruskal-Wallis was conducted and the results of which were presented as follows:

- H0: There is no correlation between renal cells histopathology in at least a pair of treatment group.
 H1: There is correlation between renal cells histopathology in at least a pair of treatment group.

Table 1. The Kruskal-Wallis Results.

	PA
Chi-Square	19.841
Df	2
Asymp. Sig.	.000

Grouping Variable: Treatment.

The results of statistical analysis of Kruskal-Wallis by F test in the renal cells histopathology showed a value of $p < 0.05$, meaning that there is a very significant difference of necrosis levels of tubular renal cells in at least a pair of treatment group. To determine the group that caused a different effect on the renal cells histopathology, an advanced test was carried out. Below was the result of the Mann-Whitney post hoc test by aid of SPSS software.

Table 2. Mann-Whitney Advanced Test of each Treatment Group.

Dependent Variable: Histopathology

Histopathology	Sham vs Treatment	Sham vs Control	Control vs Treatment
Mann-Whitney U	16.000	0.000	12.000
Wilcoxon W	71.000	55.000	67.000
Z	-2.682	-3.882	-2.941
Asymp. Sig. (2-tailed)	.007	.000	.003
Exact Sig. [2*(1-tailed Sig.)]	.009 ^b	.000 ^b	.003 ^b

Grouping Variable: Treatment (Sukun leaf).

Table 3. Eta Correlation Ratio.

			Value
Nominal by Interval	Eta	Breadfruit left treatment PA Dependent	.643
			.847

Based on the table above it could be concluded as follows:

- The renal cell histopathology score in sham group differed significantly from control group ($p < 0.05$).
- The renal cell histopathology score in sham group differed significantly from treatment group ($p < 0.05$).
- The renal cell histopathology score in control group differed significantly from treatment group ($p < 0.05$).
- There was correlation between groups according to Eta correlation coefficient, with correlation ratio value 0.847, with renal cells histopathology score as dependent variable.

The test was performed to compare the cystatin C level in at least a pair of treatment group. Therefore, a statistical analysis of variance (ANOVA) was conducted the results of which were presented as follows:

- H0 : There is no difference of cystatin C levels in at least a pair of treatment group.
 H1 : There is difference of cystatin C levels in at least a pair of treatment group.

The results of statistical analysis of ANOVA by F test in the mean cystatin C levels showed a value of $p < 0.05$, meaning that there is a very significant difference of cystatin C levels generated in at least a pair of treatment group. To determine the treatment group that caused a different effect on the cystatin C levels generated, an post hoc Benferroni test was carried out. Based on Benferroni test, the result could be concluded as follows:

Table 4. The ANOVA Results of Mean Cystatin C Levels.

	Sum of Squares	Df	Mean Square	F	Sig.
Between Groups	3187940.600	2	1593970.300	7.062	.003
Within Groups	6093832.100	27	225697.485		
Total	9281772.700	29			

- The cystatin C level in sham group differed significantly from control group (p-value<0.05).
- The cystatin C level in sham group was not significantly different from treatment group (p-value>0.05).
- The cystatin C level in control group was not significantly different from treatment group (p-value>0.05).

DISCUSSION

In acute ischemia/reperfusion injury, renal ischemia caused cell damage and cell death by the depletion of cellular energy, where there occurred an accumulation of sodium, calcium, and reactive oxygen in intracellulars, and activation of multiple enzyme system.^{2,6,16} Though reperfusion is vital in preventing tissue death, it may also cause secondary local damage due to acute inflammatory responses involving a tissue infiltration activated by platelet and polymorphonuclear leucocyte.^{5,8} The tissue damage is mediated by cytokine, a local imbalance between nitrite oxide levels and superoxide.^{3,4,8}

The results of this study show that the administration of sukun leaf extract significantly improves the condition of renal ischemia-reperfusion damage when seen from histopathologic parameters of renal cells. Several studies of renal ischemic reperfusion injury have shown that histopathologic features after experimental intervention can assess changes in glomerular damage, renal tubules, necrotic levels, and leukocyte infiltration.^{15,17}

This study has shown that pre-treatment with sukun leaf extract can decrease renal damage through the protective effects of quercetin in renal tubular cells and inhibition of leukocyte infiltration into renal tissue. This is consistent with other studies investigating the effects of quercetin on reperfusion ischemia injury models in rabbit muscle, where quercetin can balance NO and superoxide levels.⁸ Low-concentration nitric oxide acts as a renoprotective agent against renal ischemia, as it can serve as a vasodilator, anti-inflammatory, and antioxidants.¹⁸

However, in this study, sukun leaf extract did not significantly affect the condition of renal function based on the serum cystatin C parameters. This may occur due to the small number of samples, reduced breadfruit leaf concentration due to previous intraperitoneal anesthesia agent, damaged cystatin C reagents, or previous renal function impairment prior to left kidney nephrectomy. Cystatin C itself was chosen as a renal function test because it can indirectly assess GFR¹⁷⁻¹⁸ and favourable compared to other tests, such as NGAL, KIM-1, or renal scintigraphy, due to limited facilities in the author's laboratory.

For follow-up studies, total oxidant status, total antioxidant status, and malonaldehyde test¹⁷⁻¹⁸ can be assessed for oxidative or free radical damage before and after surgery/intervention. It is necessary to determine whether there was free radical damage before the experimental intervention is performed.

CONCLUSION

The histopathologic parameter shown that sukun leaf extract can improve significantly the condition of renal ischemia-reperfusion injury. However, from serum Cystatin C parameter, administering sukun leaf extract did not affect significantly renal function.

REFERENCES

- Prodjosudjadi, Wiguno, dan Suhardjono A. End-stage renal disease in Indonesia: treatment development. *Ethnicity & Disease*. 2009; 19: 33-6.
- Bonventre, Joseph V, and Yang Li. Cellular pathophysiology of ischemic acute kidney injury. *Journal of Clinical Investigation*. 2011; 121(11): 4210-4221
- Carden, Donna L, and Granger, D Neil. Pathophysiology of ischemia-reperfusion injury. *The Journal of Pathology*. 2000; 190(3): 255-266.
- Riera M, Torras J, Herrero I, Valles J, et al. Neutrophils accentuate renal cold ischemia-reperfusion injury. Dose-dependent protective effect of a platelet-activating factor receptor antagonist. *The Journal of Pharmacology and Experimental*

- Therapeutics. 1997; 280(2): 786-794.
5. LC Racusen and Nast CC. Renal Histopathology, Urine Culture, in Atlas of diseases of the kidney 2. Oxford. 2004.
 6. Tighe JR. The pathology of renal ischemia. J. Clin. Path. 1997.
 7. SVR Ganeson, IR Husen and Siregar, Safendra. Protective Effect of Sukun Leaf Infusion on Gentamicin Induced Acute Kidney Injury. 2012.
 8. Huk I, Brovkovych V, Nanobash Vili J, Weigel G, et al. Bioflavonoid quercetin scavenges superoxide and increases nitric oxide concentration in ischemia-reperfusion injury: an experimental study. The British Journal of Surgery. 1998; 85(8): 1080-1085.
 9. Küçük A, Yucel M, Erkasap N, Tosun M, et al. The effects of PDE5 inhibitory drugs on renal ischemia/reperfusion injury in rats. Molecular Biology Reports. 2012; 39(10): 9775-9782.
 10. Singh, Amrit Pal, Junemann, Anselm, Muthuraman, Arunachalam, Jaggi, Amteshwar Singh, et al. Animal models of acute renal failure. Pharmacological reports: PR. 2012; 64(1): 31-44.
 11. Wei Q, and Dong Z. Mouse model of ischemic acute kidney injury: technical notes and tricks. AJP: Renal Physiology. 2012; 303(11): F1487-F1494.
 12. Zaher Armaly, Zaid Abassi. Phosphodiesterase-5 Inhibitors: Potential Nephroprotective Agents. Clinical & Experimental Pharmacology. 2014; 4(3).
 13. Mares, Jan, Stejskal, David, Vavrousková, Jitka, Urbánek, Karel, et al. Use of cystatin C determination in clinical diagnostics. Biomedical Papers of the Medical Faculty of the University Palacky, Olomouc, Czechoslovakia. 2003; 147(2): 177-180.
 14. Sohotnik R, Nativ O, Abbasi A, Awad H, et al. Phosphodiesterase-5 inhibition attenuates early renal ischemia-reperfusion-induced acute kidney injury: assessment by quantitative measurement of urinary NGAL and KIM-1. AJP: Renal Physiology. 2013; 304(8): F1099-F1104.
 15. Guzeloglu, Mehmet, Yalcinkaya, Fatih, Atmaca, Soner, Bagriyanik, Alper, et al. The Beneficial Effects of Tadalafil on Renal Ischemia-Reperfusion Injury in Rats'. Urologia Internationalis. 2011; 86(2): 197-203.
 16. Oruc, Ozgur, Inci, Kubilay, Aki, Fazil Tuncay, Zeybek, Dilara, et al. Sildenafil attenuates renal ischemia-reperfusion injury by decreasing leukocyte infiltration. Acta Histochemica. 2010; 112(4): 337-344.
 17. Ozbek, Kerem, Ceyhan, Koksall, Koc, Fatih, Sogut, Erkan, et al. The protective effect of single dose tadalafil in contrast-induced nephropathy: An experimental study. Anadolu Kardiyoloji Dergisi/The Anatolian Journal of Cardiology. 2015; 15(4): 306-310.
 18. Malek, Maryam. Renal ischemia/reperfusion injury; from pathophysiology to treatment. 2017.