

MATURE TESTICULAR TERATOMA IN PEDIATRIC PATIENT: A CASE REPORT

¹Gugum Indra Firdaus, ²Jufriady Ismy.

¹Department of Urology, Faculty of Medicine/Padjadjaran University, Bandung.

²Urology Division, Department of Surgery, Faculty of Medicine/Syiah Kuala University, Zainoel Abidin Hospital, Banda Aceh.

ABSTRACT

Objective: To report our experience on management of testicular teratoma in pediatric patient. **Case(s) presentation:** A 2-years-old boy presented with progressive mass in his left testis. The mass was found 3 months ago but became larger in a few days. The patient had no other genitourinary complaint. Vital signs were within normal limits. A hard and tender mass in the left scrotum sized 5x4x2.5 cm was palpated from the physical examination. An imaging study with Computed Tomography (CT) Scan revealed an enhancement in the left scrotum mass area. There was no ring enhancement in pelvic and paraaortic lymph nodes. The laboratory examination within normal limit. Inguinal radical orchiectomy was performed, and histopathological examination revealed a mature testicular teratoma of the left testis. **Discussion:** Testicular teratoma in children is usually benign. Testicular germ cell tumors generally have a good prognosis with current therapy. Post-orchiectomy management depends on the histology type, staging, and tumor markers. **Conclusion:** Testicular teratoma is a rare case and can cause minimal symptoms until it grows significantly. Testicular teratoma should be considered in the differential diagnosis of non-traumatic painless progressive scrotal mass. Inguinal radical orchiectomy may be considered as the primary management.

Keywords: Pediatric, teratoma, testicular, radical orchiectomy.

ABSTRAK

Tujuan: Melaporkan pengalaman kami dalam menangani kasus teratoma testis pada anak. **Presentasi kasus:** Seorang anak laki-laki berusia 2 tahun dengan massa di testis kiri yang membesar secara progresif dan terdeteksi oleh ibunya pada saat melakukan pemeriksaan testis pada skrotum yang bengkak. Orang tua pasien mengeluhkan massa pada skrotum tersebut sejak 3 bulan lalu, tetapi membesar dalam beberapa hari terakhir. Tidak ada keluhan genitourinari lainnya. Tanda-tanda vital dalam batas normal. Pemeriksaan fisik melalui inspeksi dan palpasi ditemukan masa keras dan nyeri pada skrotum kiri berukuran 5x4x2.5 cm. Pemeriksaan computed tomography (CT) scan ditemukan gambaran penyangatan cincin pada area massa skrotum kiri, tidak ditemukan penyangatan cincin pada kelenjar getah bening pelvis dan paraaorta. Pemeriksaan laboratorium, termasuk penanda tumor, normal. Dilakukan orkiektomi radikal inguinal dan pemeriksaan histopatologi ditemukan teratoma testikular matur pada testis kiri. **Diskusi:** Teratoma testis pada anak biasanya bersifat jinak. Tumor germ cell testis secara umum memiliki prognosis yang baik dengan terapi terkini dan manajemen pasca orchiectomy tergantung tipe histologi, staging, dan tumor marker. **Simpulan:** Teratoma testis merupakan kasus langka dan dapat memiliki gejala minimal hingga membesar secara signifikan. Teratoma testis perlu dipertimbangkan sebagai diagnosis banding pada massa skrotum kanan non-traumatik progresif, dan tidak nyeri. Orkiektomi radikal inguinal dapat dipertimbangkan sebagai tatalaksana primer.

Kata Kunci: Pediatrik, teratoma, testikular, orkiektomi radikal.

Correspondence: Gugum Indra Firdaus; c/o: Department of Urology, Hasan Sadikin Academic Medical Center, Faculty of Medicine/Universitas Padjadjaran, Indonesia. Jl. Pasteur No.38 Bandung. Phone: +62222039141. Email: drgugumif@gmail.com.

INTRODUCTION

Testicular cancer is the most common malignant neoplasm in male from the ages of 15 to 35. 95% of them are originated from germ cells, which are the primary cell type of the testis. Germ

Cell Tumors (GCT) occur at all ages, and there are clearly identified risk factors, including: congenital genital malformations such as: undescended testis, first degree family history of testicular tumors, presence of contralateral tumor, infertility and exposure to diethylstilbestrol. The yolk sac tumor

(YST), also known as endodermal sinus tumor, is the most common GCT in infants and children, accounting for 80% of them.¹

Teratoma is a type I germ cell tumors according to clinical presentation, pathology, and cytogenetics just like yolk sac tumors and are more frequent in extragonadal sites.¹ Teratoma is defined as a tumor composed of elements from two or more germinal layers: namely, ectoderm, mesoderm, and endoderm, and considered as developmental anomalies.²⁻⁴ Teratomas are composed of a wide variety of tissue foreign to the organ in which they arise; especially in the midline and para-axial location, with their most frequent location of occurrence is in the ovaries.^{3,4} When these tumors are composed of mature tissues they are classified as mature teratomas. Rarely, malignant change in the mature or immature teratomatous tissue may be seen; this may take the form of either sarcomatous or carcinomatous differentiation.²

Teratomas can cause various complications according to the occupying organ, but they are primarily unilateral and asymptomatic until they grow to a significant size. They are usually found incidentally, during clinical examination, imaging studies, or abdominal operations performed for a nonrelated indication.⁵ The gross appearance of teratoma depends largely on the elements within it, with most tumors having solid and cystic areas.⁶ Teratomas are generally associated with normal serum tumor markers, but they may cause mildly elevated serum Alpha Fetoprotein (AFP) levels.⁵⁻⁶

Teratomas do not have infiltrative character but are expansive tumors. Primary approach is total removal of the tumor, other treatment options are the radiotherapy and chemotherapy for the tumors that exhibit malignant character.⁶ Primary testicular germ cell tumors are very rare, especially in Aceh. Therefore we present a case of teratoma in the testicle that was found in a 2-year-old boy.

CASE(S) PRESENTATION

A 2-year-old boy was taken to our department in an outpatient clinic by his parent complained of a mass accompanied with pain in his left testicle for the past 3 months. The mass was felt increasing in size, first time they realized the mass was as big as a peanut until it became as big as a golf ball. The child consistently cried and was hard to fed, indicating the pain in his left scrotum. He had no other genito-urinary or bowel complaints. He was the first and only child of the family with a history of

normal delivery. There was no relevant past medical history since his birth, nor any family history of any malignancies.

On physical examination, general appearance and vital signs were within normal limits. Blood pressure was 120/80 mmHg, heart rate 100 times/ minute, respiration rate 20 times/ minute, and body temperature was 37° of Celcius. Urologic physical examination revealed in the left scrotum, a mass was palpated with a size about 5x4x2.5 cm, hard and tender (Figure 1). Laboratory examination of the Beta-HCG was normal (< 2,00 mIU/mL) and LDH was 278 U/L. The other clinical, routine blood, urine examinations, and thorax radiography were within normal limits, as well as all other routine laboratory work up.

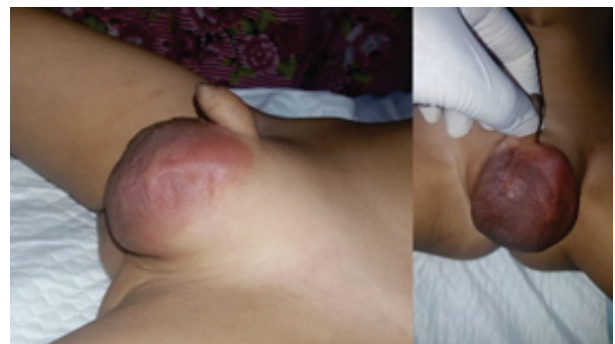

Figure 1. Physical Examination.

However, the Contrast Enhanced Multi Sliced CT-Scan of the abdomen-pelvis with axial, coronal, and sagittal slices only showed an abnormal contrast enhancement in the region of the lesion. Moreover, the Contrast Enhanced Multi Sliced CT-Scan of the pelvis with axial slices showed no contrast enhancement on the region of the pelvis (Figure 2).

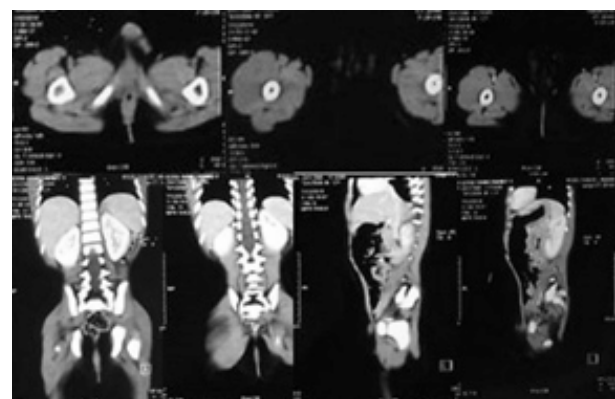


Figure 2. Contrast Enhanced Multi Sliced CT-Scan (MSCT) of Abdomen and Pelvis.

Patient was hospitalized and planned for a total surgical excision. During the operation (Figure 3), left testicle mass which was taken by orchiectomy was found with a calcified stone like mass arising with multiple hairs and debris projecting from it. A sample was taken for histopathology examination.

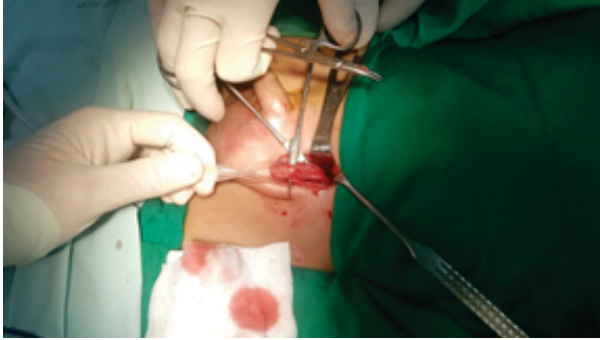


Figure 3. Intraoperative Finding

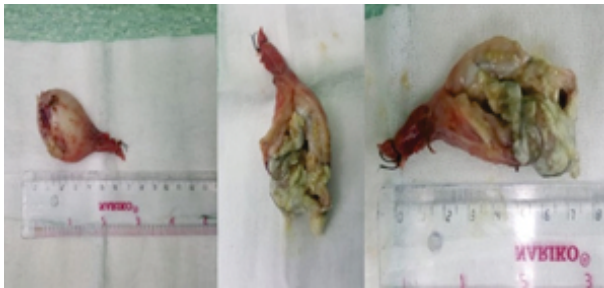


Figure 4. Macroscopic Finding of Excised Mass.

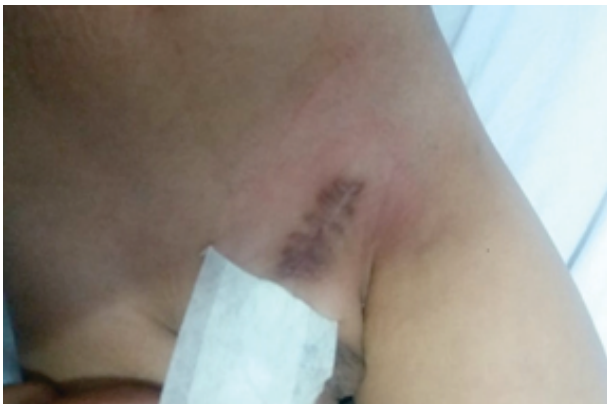

Figure 5. There was no surgical site infection after operation.

The histopathology report from the preparation showed a visible capsule tissue consisting of connective tissue with round, oval, and solid gland structures with epithelial coating, basophilic core, fine chromatin, and eosinophilic

cytoplasm. The stroma consist of connective tissue with lymphocyte cells, and congested vein. A necrotic region was also seen in a couple of places with lymphocyte and epithelial macrophage cells. These findings suggested benign teratoma. No serious problems occurred during the post-operative period, the patient was discharged 3 days after the operation and at follow-up over a 1-months period, the patient's course was uneventful (Figure 5).

DISCUSSION

Teratomas is the most nebulous and controversial member of GCT, its derived from the Greek word “tera” meaning monster, which contain well-differentiated cells from all 3 germ layers, such as hair, bone, teeth and neurons. Well-differentiated tumors are labeled mature teratomas, whereas incompletely differentiated tumors are labeled immature. Unlike immature teratomas that are malignant, mature teratoma is benign.^{5,7-8}

How germ cells fail to follow their normal developmental program, and instead begin to differentiate into somatic tissues is a fascinating problem that has yet to be solved. The parthenogenic theory, which suggests an origin from primordial germ cell, is now the most widely accepted theory of the pathogenesis.^{3,5} Teratomas undergo varying degrees of uncoordinated continuous growth.⁶ Midline teratomas, along the embryonic fusion lines, result from abnormal germ cells when the neural tube closes at about the 3rd to 5th week of embryonic life.³ Teratomas are rather commonly encountered pediatric tumors, arising from various sites, most common in sacrococcygeal and ovary.⁵

Imaging can help delineate the mass in relation to surrounding viscera and to identify any associated complications.⁵ On ultrasound (US), a mature dermoid cyst appears as a thick-walled cystic mass with echogenic contents and calcifications.⁷ However, numerous pitfalls have been described in this diagnostic modality; complicated by the various appearances of the tumors.⁹ In a prospective study, Mais et al reported a sensitivity of 58% and, specificity of 99% in diagnosing a mature cystic teratoma by US.⁵ The diagnosis by CT and Magnetic Resonance imaging is fairly straightforward, as these modalities explicitly demonstrates and more sensitive in the detection of fat attenuation within a cyst and calcifications of the wall.⁵

Reported complications depends on their size and the occupied organ, such as ovarian torsion

(16%), rupture (1-4%), malignant transformation (1-2%), infection (1%), invasion into adjacent viscera, and autoimmune hemolytic anemia (<1%).⁵ The treatment should be conservative considering the benign nature of the entity.¹⁰ but surgical excision of the lesion is the definitive treatment and histopathological examination is essential to exclude malignant transformation.⁷ The reported somatic transformations include different sarcoma and carcinomas that are commonly identified in metastatic lesions and not in the primary testicular tumour. Somatic transformation in a teratoma confers a worse prognosis and can affect the choice of surgical approach and chemotherapy regimen used for treatment.¹¹

There has been debate about the possibility of testicular teratomas malignant potential. Teratomas in the testicle in children are benign. In fact, most of the deaths in children with these tumors have been caused by the treatment. However, it's not the case with adult teratomas, where metastasize and malignant teratomas are found.¹² Testicular germ cell tumors have an overall excellent prognosis with modern therapy. Patient management after orchiectomy is determined by a number of factors, which may include histologic tumor type, pathologic T category, serum tumor markers (b-human chorionic gonadotrophin, a-fetoprotein), and radiologic stage category.¹³

CONCLUSION

Testicular teratoma is a rare case and can cause of minimal symptoms until grow to a significant size. It can be normal finding in clinical laboratory and radiological examination. Testicular teratoma should be considered in the differential diagnosis of non-traumatic painless progressive scrotal mass. Inguinal radical orchiectomy may be considered as the gold standard treatment.

REFERENCES

1. Murcia JDU, Ochoa MAS, Manrique IAV, et al. Pure Yolk Sac Testicular Tumor in an Adult Patient: Case Report. *Oncol Cancer Case Rep.*2017; 3: 1-3.
2. Ahmed T, Bosl GJ, Hajdu SI. Teratoma with Malignant Transformation in Germ Cell Tumors in Men. *Cancer.*1985; 56: 860-863.
3. Okeke LI, Ogun GO, Etukakpan BR, et al. Dermoid cyst of the urinary bladder as a differential diagnosis of bladder calculus: a case report. *J Med Case Rep.*2007; 1: 32.
4. Agrawal S, Khurana N, Mandhani A, et al. Primary bladder dermoid: a case report and review of the literature. *Urol. Int.*2006; 77: 279-280.
5. Omar M, El-Gharabawy M, Samir A, et al. Mature Cystic Teratoma of the Bladder Masquerading as a Distal Ureteral Stone. *Urol Case Rep.*2017; 13: 94-96.
6. Onen MR, Kayalar AE, Kilic A, et al. Adult Sacrococcygeal Teratoma: A Case Report. *World Spinal Column J.*2012; 3: 67-70.
7. Vera, Safriadi F. Mature (Benign) Cystic Retrovesical Teratoma in a 49-Year-Old Male: a Case Report and Literature Review. *Am J Med Case Rep.*2016; 4: 153-157.
8. Salz HK, Testicular Teratomas: Germ cells Cycling in the Wrong Direction.2016; 15: 1029-1030.
9. Tandon A, Gulleria K, Gupta S, et al. Mature ovarian dermoid cyst invading the urinary bladder. *Ultrasound Obstet Gynecol.*2010; 35: 751-753.
10. Jain SK, Kaza RC, Vindal A, et al. Vesical dermoid: an unusual presentation. *Int J Urol.* 2010; 17: 824-5.
11. Jasim A, Brown M, Laycock A. Post-Pubertal Testicular Teratoma with Somatic-Type Malignancy in the Primary Tumour: A Case Report. *Pathology.*2017; 49; 75.
12. Kedia K, Fraley EE. Adult Teratoma of The Testis Metastasizing as Adult Teratoma: Case Report and Review of Literature. *J Urol.* 1975; 114: 636-638.
13. Verrill C, Yilmaz A, Srigley JR, Amin MB, Comperat E, Egevad L, et al. Reporting and Staging of Testicular Germ Cell Tumors. *Am J Surg Pathol.*2017; 41: 22-3