

# URINARY BLADDER FOREIGN BODY: A CASE REPORT

<sup>1</sup>Santi Parambang, <sup>2</sup>Bacilius Agung Priyosantoso.

<sup>1</sup> General Practitioner, Provita Hospital, Jayapura.

<sup>2</sup> Urologist, Provita Hospital, Jayapura.

## ABSTRACT

**Objective:** This study aims to knowing the causes and symptoms is very important in determining the management. **Case(s) presentation:** A 44-year-old man came to the urology clinic with the chief complaint of painful urination after inserting an electric cable 1 meter long and 1 cm in diameter through the urethra 2 days earlier. The patient was then subjected to cystoscopy and removal of the cable using grasping forceps. **Discussion:** Urinary system foreign bodies can be caused by stimulation when the patient is conscious or under the influence of alcohol, mental disorder, curiosity to medical procedure (iatrogenic). Diagnosis of foreign bodies is based on history, physical examination and supporting examinations in the form of plain abdominal x-rays, ultrasound to CT-Scan. Removal of foreign bodies is adjusted to the type, size and location of foreign bodies in the urinary tract. **Conclusion:** Recognition of urinary system foreign bodies is very important. The various types of foreign bodies are a challenge for urologists. The selection of an appropriate operative intervention with low complications gives a good prognosis.

**Keywords:** Foreign body, electrical wire, bladder, cystoscopy.

## ABSTRAK

**Tujuan:** Penelitian ini bertujuan untuk mengetahui penyebab serta gejala klinis sangat penting dalam menentukan manajemen tatalaksana dalam kasus ini. **Presentasi kasus:** Pria usia 44 tahun, datang ke poliklinik urologi dengan keluhan utama nyeri buang air kecil setelah memasukan kabel listrik sepanjang 1 meter dan diameter 1 cm melalui uretra 2 hari sebelumnya. Pasien kemudian dilakukan sistoskopi dan pengeluaran kabel dilakukan menggunakan grasping forsep. **Diskusi:** Benda asing sistem urinaria dapat disebabkan oleh stimulasi seksual saat pasien sadar atau dibawah pengaruh alkohol, gangguan jiwa, rasa ingin tahu hingga prosedur kedokteran (iatrogenik). Diagnosa kasus benda asing berdasarkan anamnesis, pemeriksaan fisik dan pemeriksaan penunjang berupa x-ray foto polos abdomen, USG hingga CT Scan. Pengeluaran benda asing disesuaikan dengan jenis, ukuran serta lokasi benda asing dalam traktur urinaria. **Simpulan:** Pengenalan kasus benda asing traktus urinaria sangat penting. Jenis benda asing yang bervariasi merupakan salah satu tantangan bagi dokter spesialis urologi. Pemilihan intervensi operatif yang sesuai dengan komplikasi yang rendah memberikan prognosis yang baik.

**Kata kunci:** Benda asing, kabel listrik, vesika urinaria, sistoskopi.

Correspondence: Santi Parambang, c/o: Provita Hospital. Jl. Sam Ratulangi No.39 Jayapura 99112. Mobile Phone: +6282198503744. Email: ratnaliasanti12@gmail.com.

## INTRODUCTION

Cases of insertion of foreign bodies in the urinary tract are rarely reported but are an emergency condition until they become a challenge in the enforcement of diagnoses.<sup>1-2</sup> These cases most often occur on the basis of psychological disorders, the purpose of sexual gratification, reducing symptoms of urine retention, drug intoxication, migration from other organs to the consequences of medical procedures (iatrogenic).<sup>3-4</sup>

The study by Bansal et al on 49 patients in South India found that the number of cases of foreign body vesica urinaria was more men than women in a ratio of 1.3 : 1. Types of foreign objects vary greatly from wooden twigs, electrical wiring, telephone wires, DJ Stents, foley catheters, plastic materials, broomsticks, staples. IUD, pen, NGT hose, plastic doll, tongue cleaner to split bread cutter.<sup>3-6</sup>

Clinical manifestations complained of such as dysuria, frequency, nocturia, urgency, weak urine radiance to incomplete feelings of urination.<sup>7</sup>

Enforcement of the diagnosis can be done with anamnesis and an accurate physical examination although the patient is less likely to admit to having inserted a foreign body because he feels ashamed.<sup>4</sup>

It can be confirmed through radiological examination with BNO in the case of radio-opaque foreign bodies, ultrasound (Ultrasonography) to CT-Scan and Urethroscopy.<sup>4</sup> Complications that occur due to late treatment in the form of urosepsis, gangrene Fournier's, uremia, urethral strictures to fistulas.<sup>8-10</sup> The selection of surgical arrangements in the case of foreign objects must take into account the size, shape and location of the foreign object.<sup>11</sup>

### CASE(S) PRESENTATION

The male patient on behalf of Mr. A. G. aged 44 years came to the urology polyclinic with his wife with the main complaint of pain when urinating which was felt since 2 days, pain felt in the lower abdomen like slashed and radiated to the base of the penis especially when the patient wanted to urinate. Complaints of pain are felt to decrease after the patient has finished urinating. The patient also complained that it was difficult to start the voiding process so the patient had to strain and when the urine came out it only dripped and felt unfulfilled.

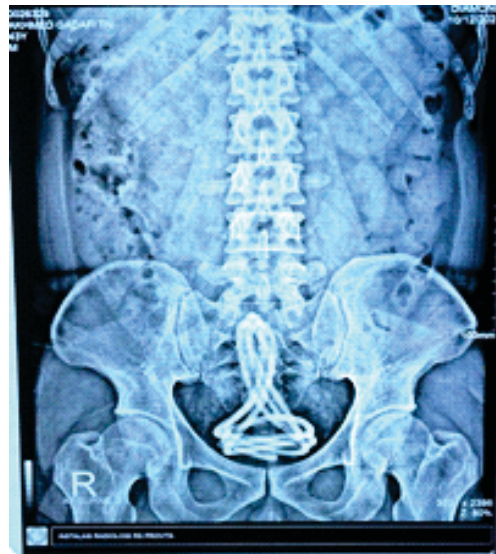After urinating, the patient admitted that he had red blood. The patient admitted that for 2 days there was a history of inserting a  $\pm$  1 meter long electric cable with a diameter of 1 cm into the genitals because at that time the patient complained that the base of the penis felt itchy and it was difficult to start urinating so the patient took the initiative to insert the cable to reduce these complaints. 2 hours after inserting the cable, the patient began to feel severe pain in the lower abdomen and then went to the emergency room of the nearest hospital and received anti-pain medication but the pain did not decrease so the patient was brought by his wife to the urology polyclinic. History of urinary stones or gonorrhea was denied.

Based on the patient confession, so far there is no use of objects as objects to achieve sexual satisfaction. The patient also lives with his wife and has active sexual intercourse with his wife on a regular basis and has never used drugs to increase sexual activity. The patient's wife also did not complain about sexual weakness in the patient. The patient is a civil servant and admits that there is currently no pressure at work.

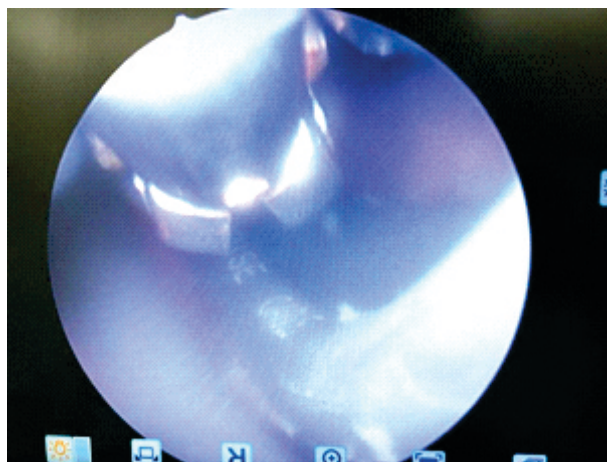
Physical examination revealed suprapubic tenderness. In the external genitalia region, no swollen and blood clots were found. Psychiatric evaluation while in hospital, namely compositentis awareness, cooperative patients, and wearing clothes neatly, according to age. The patient appears calm, orientated towards time, place and person is good and appropriate. His psychomotor activity was within normal limits. His mood is euthymic. The associations are appropriate, and cognitive function is within normal limits. no perceptual disturbances or hallucinations were found. The patient can answer the doctor's questions very calmly and sequentially. Physical and neurological examinations did not reveal any pathological abnormalities.

Examination with a KUB photo and found metal density in the pelvic cavity (Fig 1). In the laboratory results found blood in the urine 3+. The patient was then performed an emergency cystoscopy using a rigid cystoscope and the urinary bladder was found to have a foreign body 1 meter long electric wire (Fig 2) and hyperemic bladder mucosa. The foreign body was then removed using grasping forceps (Fig. 3) and the electrical cord was successfully removed without any residue in the bladder (Fig. 4).

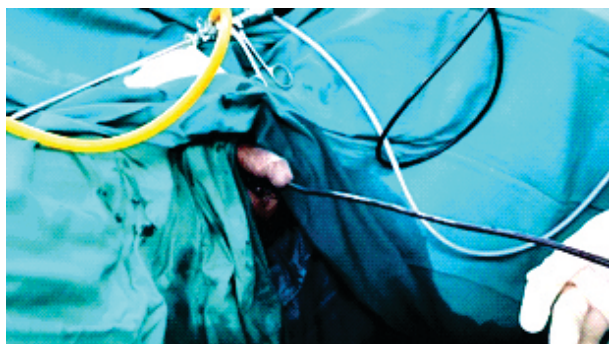The patient was then given the antibiotic Ceftriaxone 2 grams per 24 hours for 3 days and the patient was allowed to go home without complications.



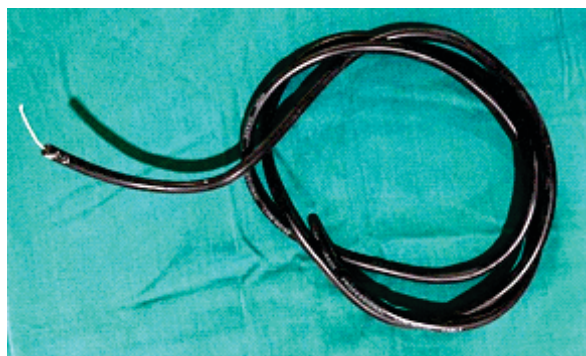**Figure 1.** Abdomen BNO X-ray shows the presence of metal density shadows in the pelvic cavity.



**Figure 2.** Cystoscopy shows electrical wires in the bladder



**Figure 3.** Foreign body withdrawn using grasping forceps



**Figure 4.** Electrical Wire.

## DISCUSSION

Cases of electric wire foreign bodies in the urinary system have been reported in several studies.<sup>3,4,12</sup> The most common causes in cases of foreign bodies in the urinary system are

psychological disorders, the purpose of sexual satisfaction, reducing urinary retention symptoms, drug intoxication, migration from other organs to medical procedures (iatrogenic).<sup>3-4</sup> The number of cases of foreign body migration increases in women related to the anatomy of a shorter and straighter urethra than men.<sup>13</sup> In the modern era, the increase in the use of endoscopic instruments plays a role in the increase in the incidence of foreign bodies due to medical action (iatrogenic).<sup>4</sup>

Enforcing the diagnosis of foreign body cases is quite difficult and challenging. Many patients do not admit to having inserted a foreign body into the genital area because of embarrassment or because of an underlying mental illness that is aggravated by nonspecific symptoms. risk of migration to other organs.<sup>14</sup>

The physical examination can be adjusted according to the type of foreign body inserted. Foreign bodies distal to the urogenital diaphragm are easily palpable. Investigations can be carried out by laboratory examinations where the microscopic results of urine contain pus and red blood cells. Confirmation using radiological modalities is used to assess the size, shape, number, position and orientation of foreign bodies. BNO photos can be done for radio-opaque objects and ultrasound for radio-lucent objects. CT-Scan can be used in patients with complications of peritonitis or suspicion of foreign body migration.<sup>4,6,9</sup> Flexible cystourethroscopy is the most accurate method for diagnosing bladder foreign bodies.<sup>4</sup>

Management of patients with foreign body cases with foreign body expulsion without or with minimal trauma and considering and looking at the patient's condition, age, size, shape, location, mobility and whether the chosen technique can injure the urethra and interfere with erectile function.<sup>15-16</sup>

The endoscopic method should be used if it is assessed that there is no potential for urethral injury, but if this is not possible then open surgery should be performed. Removal of foreign bodies is performed by transurethral cystoscopy using grasping forceps or transurethral cystolitholaxy using a stone crusher. Rigid and flexible cystoscopy can be used to remove intra-vesical foreign bodies. Cystourethroscopy is also important for diagnosing the presence of a urethral incision and ensuring that all foreign objects have been removed.<sup>2,10,15</sup>

In certain situations, more invasive foreign body extraction procedures such as external

urethrotomy, suprapubic cystostomy or meatotomy may be required.<sup>17</sup>

Complications that occur such as urinary tract infections, urethral strictures, uremia, sepsis to penile necrosis can occur due to delayed treatment. Urethral stricture is the most common complication with an incidence of 5%.<sup>17-19</sup>

## CONCLUSION

Recognition of foreign body cases of urinary system is very important. The various types of foreign bodies are a challenge for urologists.

Cases of foreign bodies can be caused by psychological disorders, sexual stimulation as the most common cause, curiosity or curiosity. Selection of an appropriate surgical method with low complications provide a good prognosis.

## REFERENCES

1. Tuncer H, Karacam H, Cam B. A Self-Inserted Foreign Body in the Urinary Bladder and Urethra. *Cureus*. 2021; 13(7): e16322.
2. Ahmed M, Pawar P, Sawant A. et al. Foreign Body in Urinary bladder: Our Experience and Review of Literature. *Int Surg J*. 2019; 6(12): 4327-4331.
3. Mahadevappa N, Kochhar G, Vilvathy KS, Dharwadkar S, Kumar S. Self inflicted foreign bodies in lower genitourinary tract in males: our experience and review of literature. *Urol Ann*. 2016; 8(3): 338e342.
4. Bansal A, Yadav P, Kumar M, Sankhwar S. et al. Foreign Bodies in the Urinary Bladder and Their Management: A Single-Centre Experience From North India. *Int Neurourol J*. 2016; 20: 260-269.
5. Dinesh A, Singh A, Neogi S. Tongue cleaner, an unusual foreign body in the urethra: A case report. *AMJ* 2013; 6(10): 508-510.
6. John J, Kesner K. Urethral polyembolokoilomania: not a bread-and-butter issue. *Ther Adv Urol*. 2021; Vol. 13-14.
7. Soomro H, Jalbani IK, Faruqui N. Intravesical foreign body: tertiary care center experience from Pakistan. *J. Pak Med Asso*. 2016; 66: 131-3.
8. Khoo JR, Wu GTC and Yeung BKF. Re: Per urethral insertion of foreign body for erotism: case reports. *Hong Kong Med J*. 2019; 25: 498.
9. Palmer C, Houlihan M, Psutka S, Ellis K, Vidal P, Hollowell C. Urethral foreign bodies: clinical presentation and management. *Urology*. 2016; 97: 257-60.
10. Naidu K, Chung A, Mulcahy M. An unusual urethral foreign body. *Int J Surg Case Rep*. 2013; 4: 1052-4.
11. Palmer CJ, Houlihan M, Psutka SP, Ellis KA, Vidal P, Hollowell CM. Urethral foreign bodies: clinical presentation and management. *Urology* 2016; 97: 257-60.
12. Ahn H, Son H. Successful Removal of an Intravesical Electrical Wire Cable. *World J Mens Health*. 2014; 32(2): 120-122.
13. Lima S, Cebola A, Pereira S. et al. Self-Insertion of Foreign Bodies in Urethra and Bladder: Report of Three Pediatric Cases. *ACTA Urologica Portuguesa*. 2019; 36: 3-4.
14. Oksay T, Ozorak A, Ergun O, BurakHoscan M, Kosar A, Serel TA. Percutaneous Removal of a Very Unusual Foreign Body from the Bladder: Case Report and Literature Review. *JAEM*. 2013; 12: 231-3.
15. Fath elbab T, Abdelhamid A, Galal E, Anwar A, Malek M, Tawfik E. Mana-gement of intravesical self-inflicted sharps objects in children: 10-year single-center experience. *JPurol*. 2016; 12: 97. e1-97.e5.
16. Rahmani M, Shakiba B, Ameli M. Management of an extremely long foreign body in the urethra and bladder of a 13-year-old boy: a case report. *Thrita J Med Sci*. 2013; 2: 35-7
17. Hedge A, Choubey S, Kanagali R, Pipara G, Rao A, Mohan A. Listening to his inner voice? An unusual urethral foreign body: A review of literature and few learning points. *Asian J Urol*. 2018; 5: 131-2.
18. Labine MA, Cappello M, Skogberg J. et al. Case report: Caustic foreign body insertion into the male urethra. *J.eucr*. 2020; 33.
19. Palmer C, Houlihan Matthew, Psutka S, Ellis A. Urethral Foreign Bodies: Clinical Presentation and Management. *J Urology*. 2016; 5(45).